

# JOINT TRAUMA SYSTEM CLINICAL PRACTICE GUIDELINE



## Pelvic Fracture Care

Provides a brief review for the stabilization and treatment of pelvic fractures sustained in combat casualties.

### CONTRIBUTORS

MAJ Stephanie Saint Laurent, MC, USA  
CDR Christopher S. Smith, MC, USN  
LCDR Erica K. Crump, MC, USN  
CAPT Bradley K. Deafenbaugh, MC, USN

Lt Col Remealle A. How, USAF, MC  
CAPT Matthew D. Tadlock, MC, USN  
CDR J. Michael Van Gent, MC, USN  
COL Jennifer Gurney, MC, USA

Previous contributors: LtCol Wade Gordon, USAF, MC; CDR Mark Fleming, MC, USN; LTC Anthony Johnson, MC, USA; Col Stacy Shackelford, USAF, MC; CAPT Zsolt Stockinger, MC, USN

Original publication date: 18 Dec 2004 | Publication Date: 17 Feb 2026 | Supersedes: 15 Mar 2017

### TABLE OF CONTENTS

BACKGROUND.....	3
EVALUATION AND TREATMENT.....	4
Hemorrhage Control.....	5
Evaluation of Associated Injuries.....	6
TEMPORARY PELVIC STABILIZATION.....	7
PERFORMANCE IMPROVEMENT (PI) MONITORING.....	8
REFERENCES.....	9
APPENDIX A: PELVIC FRACTURE CLINICAL PATHWAY.....	11
APPENDIX B: PELVIC PACKING TECHNIQUE.....	12
APPENDIX C: PELVIC STABILIZATION TECHNIQUE.....	14
APPENDIX D: CLASS VIII MEDICAL MATERIEL.....	16
APPENDIX E: TELEMEDICINE / TELECONSULTATION.....	17

### SUMMARY OF CHANGES

- Background expanded to include combat casualty data and pelvic fracture classifications.
- Temporary pelvic stabilization techniques expanded (sheets and binder).
- Added preperitoneal packing considerations and techniques.
- Pelvic external fixation technique added.

# PELVIC FRACTURE CARE

## PELVIC FRACTURE IN COMBAT

- Increasing in frequency
  - IEDs/DISM ops/high energy weapons
- 71% open pelvic fracture (50% mortality)
- AP compression Fx > Lat compression Fx
  - ↑ procedural hemorrhage control req.
- Assoc LE amputation (63%) Bilat AKA (39%)

## 4 TENETS OF PELVIC FRACTURE MGMT

1. Resuscitate w/whole blood/balanced components
2. Stabilize bony pelvis
3. ID source of hemorrhage: include chest/Abd/rectum/genitalia
4. Hemorrhage control

## TEMPORARY PELVIC STABILIZATION

### Pelvic Binder/Compression Sheet

- 70% of hemorrhage venous--only fills available space—  
***pelvic binder reduces volume/aid clot formation***
- Binder or compression sheet between greater and lesser trochanters/buckle over pubis → Primary survey
  - Taping knees and ankles together can minimize external rotation/improve pelvic reduction
- Add Pelvic X-ray to primary survey--binder temp released if possible (13% of AP compression FXs missed)
  - Pressure ulcers as soon as 3-4 hrs/ skin checks q 12 hrs/ definitive fixation w/in 24 hrs

### Unstable Pelvic FX → Whole Blood → OR

#### Positive FAST

- Laparotomy/hemorrhage control
- Preperitoneal packing via separate incision
- Pelvic stabilization (ex fix or pelvic binder)

#### Negative FAST

- Preperitoneal packing
- Pelvic stabilization (ex fix or pelvic binder)
- Consider REBOA if resourced

## HEMORRHAGE CONTROL

### Preperitoneal packing (PPP) – Lap Pads along pelvic ring to tamponade venous and bony bleeding

#### Indications

- SBP < 90 despite binder+ transfusion
- +FAST w/ pelvic hematoma
- Unstable after exlap/hemorrhage control
- Unstable pelvic fx in austere environment
- Separate procedure from Ex-Lap

#### Steps

- Lower midline incision/divide linea alba
- Leave peritoneum INTACT/evac any hematoma
- 3-4 rolled packs each side of space of Retzius
- Deep in pelvic/compress iliac veins/venous plexus.
- Close skin or fascia over packs

### Stabilize Pelvis at same time (Binder/Ex Fix)/Continue Resuscitation/Remove Packs in OR in 24-48hrs

- Angio Embolization (AE) can be considered if continued bleeding despite PPP and properly resourced
- Internal Iliac (Hypogastric) Artery Ligation if AE not available, but risks gluteal muscle necrosis

## EXTERNAL FIXATION OF PELVIS (Iliac Crest Technique)

### Anatomy

- Two fingerbreadths posterior to ASIS
- Dissect soft tissues to expose inner/outer table
- 2nd pin posterior to that

### Pearls/Pitfalls

- Aim towards contralateral greater trochanter
- Rest pin along inner table to demarcate slope
- Achieve closed reduction prior to tightening

### METRICS

- ✓ Hemodynamically unstable patients (SBP < 100, or 110 in patients with suspected traumatic brain injury, or HR > 100) with a pelvic ring injury, received pelvic stabilization with appropriately placed sheets or binders.
- ✓ Patients with pelvic fracture and a positive FAST who remain hemodynamically unstable after blood resuscitation, undergo hemorrhage control procedure (exploratory laparotomy, preperitoneal packing, external fixation or pelvic binder at minimum) at the same level of care where diagnosed.
- ✓ Patients with unstable pelvic fracture and a negative FAST who remain hemodynamically unstable after pelvic binder placement and blood resuscitation, undergo hemorrhage control procedure (external fixation and preperitoneal packing or interventional radiology angioembolization, if capability available) at the same level of care where diagnosed.



This information is pulled from the evidence-based Joint Trauma System (JTS) Pelvic Fracture Care Clinical Practice Guideline (CPG). JTS CPGs can be found at the [JTS CPG website](#) or the [JTS Deployed Medicine site](#).

---

## BACKGROUND

---

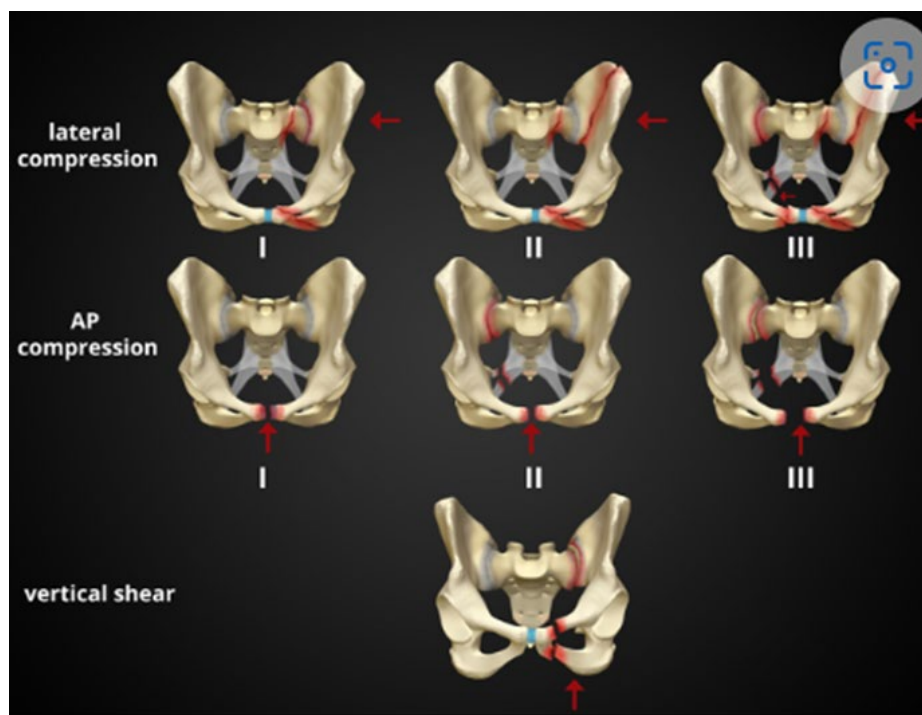
Traumatic pelvic fractures in the hemodynamically unstable patient are one of the more complex injury patterns to manage in trauma care. While only an estimated 9% of blunt trauma patients sustain an injury to the pelvis, the overall mortality rates in the setting of major pelvic injuries are reported to be 13-56%, with greater than 40% mortality rate in hemodynamically unstable patients, and 50% mortality rate for open pelvic fractures.<sup>1-7</sup> More than 70% of the bleeding that occurs in the setting of pelvic fractures is from the pelvic venous plexus, 15-25% of the bleeding is arterial requiring procedural intervention, and the remainder is from cancellous bone surfaces.<sup>1, 3-5</sup> Features predictive of needed procedural hemorrhage control are:

1. Injury severity score
2. Advancing age
3. Blood product transfusion
4. Open pelvic fractures
5. Pelvic fracture pattern, specifically:
  - a. Vertical shear
  - b. Type III anterior-posterior compression<sup>8-9</sup>

Historically, these injuries were relatively uncommon in the combat environment. However, during the Global War on Terror (GWOT), improvised explosive device (IED) attacks were common and resulted in an increased incidence of traumatic pelvic injuries from either dismounted operations or attacks against tactical vehicles.<sup>1</sup> Combat-related pelvic fractures tend to be more complex, more difficult to classify, and more commonly open than those seen in civilian trauma.<sup>7</sup> The mean Injury Severity Score (ISS) for patients with combat-related pelvic fractures is 31 versus a mean ISS of 15 seen in civilian trauma centers<sup>7</sup> due to the fact that combat related pelvic ring injuries tend to be high-energy, unstable injuries, and frequently require procedural intervention and operative fixation.

Studies have found that 71% of combat-related pelvic fractures were open fractures, complicating open fracture management, as they have higher associated mortality and morbidity rates compared to the closed pelvic fractures more commonly seen in civilian trauma.<sup>10</sup> Twenty-six percent of Service Members who died during Operations Iraqi and Enduring Freedom had a pelvic fracture.<sup>11</sup> Other differences between combat-related and civilian pelvic injuries include a higher association with lower extremity amputations, which was seen in 63% of pelvic fractures and 39% had bilateral, traumatic above the knee amputations. The most common Young-Burgess classification (Figure 1) of pelvic fractures seen in combat environments were anterior-posterior compression (APC) fractures, compared to civilian settings where the most common type is lateral compression (LC). The APC fracture pattern increases the likelihood of requiring procedural hemorrhage control: 72% of APC injuries require procedural hemorrhage control compared to only 25% of LC injuries.

Figure 1. Young-Burgess Classification



Source: [https://www.northerntrauma.co.nz/adult\\_trauma/pelvic-binders/](https://www.northerntrauma.co.nz/adult_trauma/pelvic-binders/)

## EVALUATION AND TREATMENT

**NOTE:** Refer to [Appendix A: Pelvic Fracture Clinical Pathway](#), [Appendix B: Pelvic Packing Technique](#), and [Appendix C: Pelvic Stabilization Technique](#)

Mechanism of injury (e.g., IED blast, crush injury, and high velocity penetrating wounds to the pelvis) and hypotension can indicate high risk for pelvic fracture. Care for casualties with pelvic fractures ideally starts in the prehospital environment with initiation of Tactical Combat Casualty Care (TCCC) interventions to include early blood transfusion, Tranexamic acid (TXA), and pelvic binder placement. If suspicion is high for an unstable pelvic fracture (if not already placed in the prehospital setting), pre-position binders/sheet on the litter (bed) prior to transferring the patient over, so that a binder/sheet may be utilized quickly. Signs of pelvic fracture on physical exam include pain on palpation, leg length discrepancy with foreshortening and internal rotation of the lower extremity, and a perineal hematoma which can look like scrotal bruising in men.

The four tenets of hemorrhage control in the unstable pelvic fracture:

- Resuscitation with whole blood or balanced component blood products
- Stabilization of the bony pelvis
- Identify the sources of hemorrhage
- Hemorrhage control.<sup>12</sup>

Two key determinations must be made in patients with pelvic fractures: hemodynamic stability and if the pelvic fracture is mechanically stable. If the patient is not hemodynamically stable, it is imperative to identify all site(s) of hemorrhage, as pelvic fractures often occur in conjunction with other life-threatening injuries. **Appropriate evaluation of the chest, abdomen, extremities, and other potential sites of hemorrhage cannot be overemphasized. Additionally, a thorough examination of the pelvis and perineum is required to rule out associated injuries to the rectum and genitourinary/gynecologic systems.** Open pelvic fractures have a higher morbidity; if there is concern for an open pelvic

fracture a rectal and vaginal exam must be performed. Additionally, injury to the urethra and bladder should be ruled out. Urethral injury is more common in men.

The steps to initially evaluate and treat patients with pelvic fractures are as follows:

## HEMORRHAGE CONTROL

1. All trauma patients should undergo a rapid trauma assessment according to TCCC, Advanced Trauma Life Support (ATLS), and Joint Trauma Systems (JTS) damage control resuscitation guidelines. Sources of hemorrhage should be rapidly identified and intervened upon in a systematic way. Please see [JTS Damage Control Resuscitation and Whole Blood Transfusion CPGs](#) for more information.
2. Patients in hemorrhagic shock should be appropriately treated with blood products, preferably whole blood. Blood product administration of either whole blood (preferably) or component blood products in a 1:1:1 ratio, based on available product, should be initiated for patients who remain hypotensive (SBP < 100, or 110 in patients with suspected traumatic brain injury). Initiation of massive transfusion protocol is often required.
3. During resuscitation, place a pelvic binder or sheet (if not already in place) centered over the greater trochanters with the buckle centered over the pubic symphysis. The pelvis should be manually reduced by internally rotating the hemipelvises together, having one person press the greater trochanters together after which a second person tightens down the binder or tightly secure the sheet. Taping the knees and feet together can assist in internal rotation of the lower extremities to facilitate further reduction at the pelvis and help improve the pelvic reduction achieved with a sheet or binder.<sup>14</sup> A multidisciplinary approach with early orthopedic surgery consultation (and trauma consultation if care is being rendered prior to a Role 2) is critical for the holistic management of these complex injuries.
4. As with all trauma patients, patients with concern for pelvic injuries and those with pelvic binders in place require a pelvic x-ray as an adjunct of the primary survey. If a pelvic binder is in place, obtain the x-ray with the binder/sheet cinched down. Only if the patient is hemodynamically stable, release the binder/sheet and repeat the x-ray to evaluate for major pelvic ring disruption – if the pelvic ring is unstable, reduce the pelvis again and retighten the binder/sheet; repeat the pelvis x-ray to confirm that the pelvis is radiographically reduced. **Monitor hemodynamics continuously during this process and communicate with all members of the team when the pelvic binder is released and when it is re-applied.**
5. Identify all areas of potential hemorrhage. A focused assessment with sonography for trauma (FAST exam) should be completed as another adjunct to the primary survey to assess for intra-abdominal hemorrhage. There should be a detailed examination of soft tissue disruptions with special attention paid to the perineal area. Digital rectal exams and vaginal exams should be performed for all open pelvic fractures or if there is evidence of perineal trauma.
6. Hypotensive patients with a positive FAST should proceed directly to the operating room for laparotomy. Be mindful when extending the laparotomy incision infra-umbilically. A patient with unstable pelvis and in hemorrhagic shock from this will likely have a large pre-peritoneal (or retroperitoneal) hematoma, incising into this hematoma will decompress it and release tamponade, worsening hemorrhage.
  - a. Visualize the infraumbilical area internally when extending the laparotomy incision, or alternatively, feel for a large hematoma in this region.
  - b. If there is a pre-peritoneal hematoma confirmed, **AVOID EXTENDING THE LAPAROTOMY INCISION INFERIORLY AND AVOID INCISING THE HEMATOMA.** This is the space you must preserve for your pre-peritoneal pelvic packing to be effective.
  - c. Pre-peritoneal packing (PPP) should be considered if the pelvis is thought to be the major contributor to hemorrhage, which is best completed via an infraumbilical midline incision separate from a laparotomy incision. (See below for details.)
7. If PPP is being utilized, it is strongly recommended that concomitant pelvis external fixation be performed, if possible. Binders should only be used in this setting if equipment or skills for pelvic external fixation are lacking.

8. Zone 3 Resuscitative Endovascular Balloon Occlusion of the Aorta (REBOA) should be considered for temporary hemorrhage control if there is hemodynamic instability when providers are appropriately trained and have surgical capability. (See the JTS REBOA for Hemorrhagic Shock CPG for details.)

**NOTE: Patients are rarely suitable for definitive fixation hours after presentation to surgical capability.**

9. For patients with a negative FAST who are hypotensive (SBP < 90) despite pelvic binder placement, resuscitation with blood products should be continued on the way to the OR for PPP or interventional radiology (IR) angioembolization (if capability available) and external fixation. **(Reminder: a FAST exam that is negative/non-diagnostic does not definitively rule out hemorrhage.)**<sup>13</sup>
10. Remove pelvic binders and perform surgical stabilization with an external fixator as soon as possible.  
**If a binder is left in place for more than 6 hours, the patient will need periodic skin checks at a minimum of every 12 hours by holding the pelvis reduced and taking down the binder/sheet, assessing the skin for pressure wounds and reapplying after skin assessment. If there is concern for pressure wounds, external fixation should be performed so the binder/sheet can be discontinued.** Binders/sheets should not be left in place for more than 24 hours if possible.
11. Post PPP patients will need continued ICU-level monitoring of hemodynamics and may require continued resuscitation. These patients should be in an ICU. These casualties will require transfer to a higher level of care when they are stable for transport. Pelvic fracture patients who require any type of surgical intervention will require evacuation out of the combat theater.
12. In patients who undergo PPP, packs should be removed when resuscitation is complete and they are hemodynamically stable. This should always be accomplished within 48 hours.
13. In patients who are hemodynamically unstable despite adequate pelvic packing, bleeding is then likely from an arterial source. The treatment options include: temporizing uni/bilateral internal iliac artery occlusion (with vessel loops/Rommel tourniquets, atraumatic clamps) or evacuation to a higher level of care with IR capability. These are temporizing measures only. Bilateral internal iliac artery ligation should only be performed in extreme circumstances as the risk for necrosis and severe infection increase mortality. Unilateral internal iliac artery ligation can be used with less morbidity. Ideally selective vessel ligation (branches from internal iliac) is preferred but more technically challenging.
14. Definitive pelvic surgery should be deferred to a Role 4 facility with orthopaedic trauma surgery support and capabilities. There are circumstances where this could be done at a Role 3 MTF if the adequate expertise, imaging, and adjunct capabilities are present. During the GWOT these cases were performed at either Landstuhl or at a CONUS Role 4 MTF.

## EVALUATION OF ASSOCIATED INJURIES

1. Genitourinary - genital, urethral and bladder injuries can occur with severe pelvic injuries. A thorough examination of the genitals and perineum must be performed.
  - a. Urethra - A urethral injury should be suspected with blood at the urethral meatus or a high-riding prostate on the initial rectal exam. A urinary catheter should be gently inserted and if there is any difficulty with initial catheter placement, urethral integrity must be evaluated via retrograde urethrography.
  - b. Bladder - If gross hematuria is noted, a cystogram should be performed to rule out bladder injury. (See the [JTS Genitourinary Injury Trauma Management CPG](#).)
  - c. Testicular and vaginal injuries – examine for injuries, refer to the [JTS Genitourinary Injury Trauma Management CPG](#) for more detailed information.
2. Rectal - a digital rectal examination should be performed. If defects or blood are noted, a more thorough exam is warranted with either rigid or flexible proctoscopy to evaluate for rectal injuries. (See the [JTS High Bilateral Amputations and Dismounted Complex Blast Injury CPG](#) for more details.)



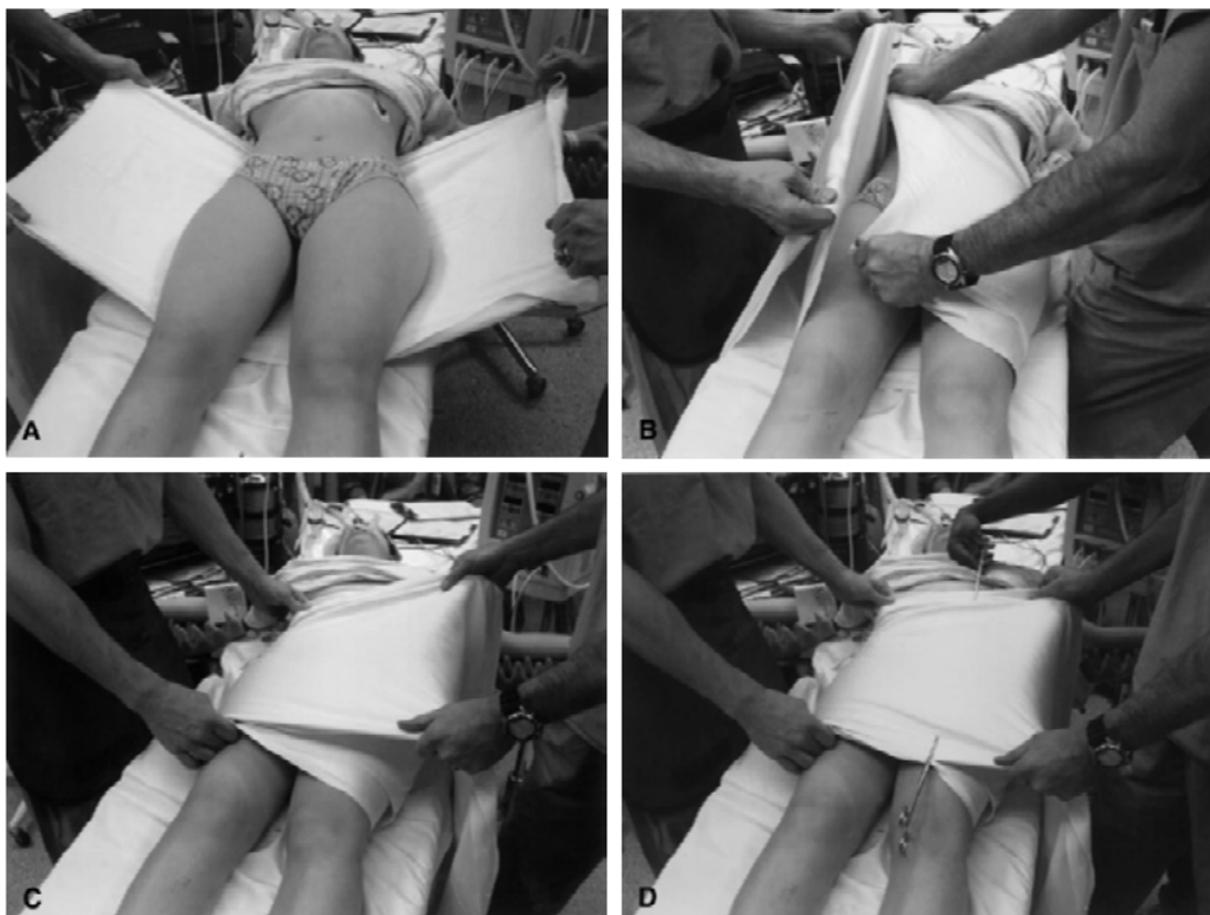3. Perineal wounds - thorough examination should be performed; perineal wounds can easily be missed and are often associated with the injuries above. See the [JTS High Bilateral Amputations And Dismounted Complex Blast Injury CPG](#) for more details.

## TEMPORARY PELVIC STABILIZATION

Pelvic stabilization can be initially accomplished with a circumferential compression device or pelvic binder. **In unstable pelvic fractures 70% of the hemorrhage is related to low pressure venous bleeding that fills available space.** Pelvic binders reduce the pelvic volume and aid in clot formation for this type of injury pattern.<sup>12</sup>

A retrospective review on civilian trauma patients with unstable pelvic fractures demonstrated that patients who had prehospital pelvic binders required fewer blood products during resuscitation and had a shorter length of hospital stay.<sup>14</sup>

**Figure 2. Pelvic Sheeting Technique** (Source: <https://musculoskeletalkey.com/pelvic-ring-injuries-2/>)



Some argue that pelvic binders can lead to an under-appreciation of pelvic ring injuries with studies showing that approximately 13% of anterior-posterior compression fractures were not appreciated on imaging with a pelvic binder in place.<sup>15</sup> The most frequently missed injuries being unstable ligamentous injuries that require surgical stabilization.<sup>11</sup> To prevent this, patients with pelvic binders/sheets in place require a pelvic x-ray as an adjunct to the primary survey, with the binder released **ONLY** if hemodynamically stable. Patients with any kind of rotational instability/displacement noted on pelvis XR should have the pelvis reduced and binder/sheet replaced immediately after the x-ray.

Pelvic binders/sheets should be transitioned to external fixation or definitive stabilization as soon as the patient is physiologically stable, and the resources are available for the procedure. There have been reports of pressure ulcerations and skin necrosis from pelvic binders when left in place for greater than 3-4 hours;<sup>16</sup> however it is not always feasible to remove the binder within this time frame due to patient instability or need to transfer to a higher level of care. Binders left

in place for prolonged periods of time should have regular skin checks at a minimum of every 12 hours, and every effort should be made to convert to either external fixation or definitive fixation (when appropriate) within 24 hours.

After pelvic stabilization and resuscitation, hemorrhage control of pelvic injuries can be accomplished through PPP, angioembolization (AE), or a combination of the two. Preperitoneal packing involves placing laparotomy pads in the preperitoneal space along the pelvic ring to tamponade both venous and bony sources of bleeding. This is a damage control procedure that requires fewer resources than AE. PPP should be first line treatment for patients who continue to be hypotensive (SBP < 90) despite appropriate binder placement and initiation of blood resuscitation, have a positive FAST requiring emergent laparotomy with a pelvic hematoma present, and have persistent hypotension despite adequate blood resuscitation and intra-abdominal hemorrhage control, or a persistently hypotensive patient with an unstable pelvic fracture in an austere environment when AE is not available. In patients with a pelvic fracture requiring exploratory laparotomy, remember to maintain the pre-peritoneal space so adequate PPP is possible.

To perform PPP an infraumbilical vertical midline incision is made and carried through the fascia, leaving the peritoneum is left intact. Bluntly enter the preperitoneal space anterior to the bladder and remove any encountered blood clot. Then place 3-4 laparotomy pads on each side of the bladder and posterior and deep into the pelvis to compress the iliac veins and pelvic venous plexus<sup>17,18</sup> Preperitoneal packing should ideally be completed at the same time as external fixation. Pelvis external fixation can be performed using two different techniques: 1) the iliac crest technique, and 2) the supra-acetabular technique. The supra-acetabular technique is not described in this CPG and should only be performed when fluoroscopy is available, and the surgical team is appropriately trained and comfortable with this technique.

Postoperatively, patients should get further resuscitation in an ICU setting. When not immediately available, the patient should be transferred to a higher level of care with ICU and potentially IR capability as soon as stable for transport. Laparotomy pads will need to be removed in the OR in 24-48 hours after being placed.<sup>17,18</sup> If there is continued pelvic bleeding despite PPP or if the patient remains hypotensive (SBP < 90) with PPP and ICU level resuscitation, AE can be attempted for further hemorrhage control when available. If AE is not available or the patient remains in extremis, unilateral or bilateral temporary internal iliac (hypogastric) ligation can be performed. However, this places the patient at risk for gluteal muscle necrosis, and this maneuver should only be performed as a “last ditch” effort.

---

## PERFORMANCE IMPROVEMENT (PI) MONITORING

---

### POPULATION OF INTEREST

Patients with pelvic fractures

### INTENT (EXPECTED OUTCOMES)

1. Patients in the population of interest with pelvic ring injury and hemodynamic instability (SBP < 100, < 110 in patients with suspected traumatic brain injury, or HR > 100) receive pelvic stabilization with an appropriately placed pelvic binder (sheets or binder).
2. Hemodynamically unstable patients with hemoperitoneum and unstable pelvic ring injury undergo preperitoneal packing and pelvic external fixation or pelvic binder (at minimum) in addition to an exploratory laparotomy.
3. Hemodynamically unstable patients with an unstable pelvic ring injury without hemoperitoneum undergo emergent preperitoneal packing or pelvic angioembolization plus pelvic stabilization (external fixation or binder).

### PERFORMANCE/ADHERENCE MEASURES

1. Hemodynamically unstable patients (SBP < 100, or 110 in patients with suspected traumatic brain injury, or HR > 100) with a pelvic ring injury, received pelvic stabilization with appropriately placed sheets or binders.
2. Patients with pelvic fracture and a positive FAST who remain hemodynamically unstable after blood resuscitation, undergo hemorrhage control procedure (exploratory laparotomy, preperitoneal packing, external fixation or pelvic binder at minimum) at the same level of care where diagnosed.



3. Patients with unstable pelvic fracture and a negative FAST who remain hemodynamically unstable after pelvic binder placement and blood resuscitation, undergo hemorrhage control procedure (external fixation and preperitoneal packing or interventional radiology angioembolization, if capability available) at the same level of care where diagnosed.

## DATA SOURCE

- Patient Record
- Department of Defense Trauma Registry

## SYSTEM REPORTING & FREQUENCY

The above constitutes the minimum criteria for PI monitoring of this CPG. System reporting will be performed annually; additional PI monitoring and system reporting may be performed as needed.

The system review and data analysis will be performed by the Joint Trauma System (JTS) Chief and the JTS Performance Improvement Branch.

## RESPONSIBILITIES

It is the trauma team leader's responsibility to ensure familiarity, appropriate compliance and PI monitoring at the local level with this CPG.

---

## REFERENCES

---

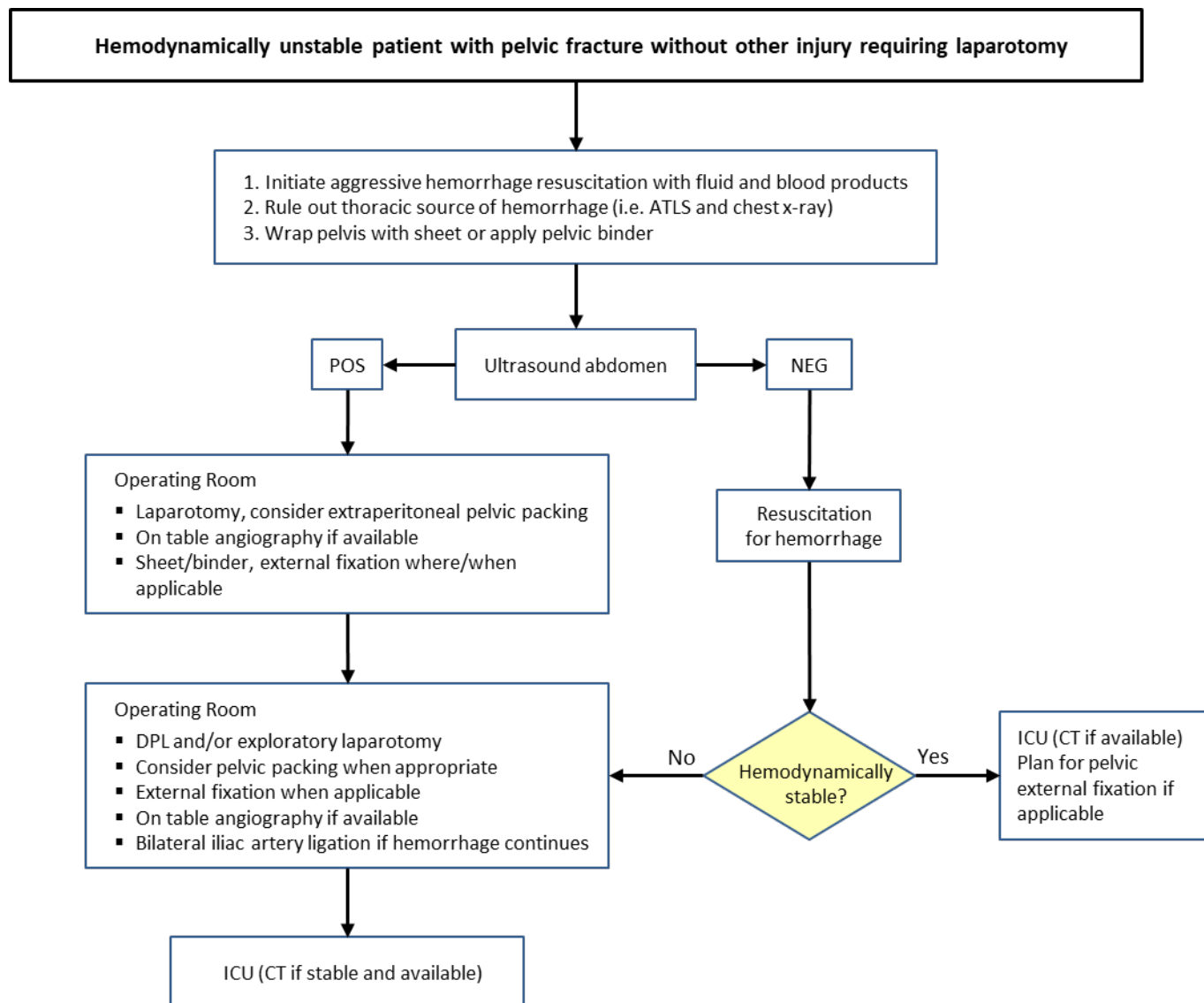
1. Lewandowski L, Kluk M, Gordon WT. Outcomes and Complications of Open Combat-Related Pelvic Fractures. Unpublished data.
2. Lopez PP. Unstable pelvic fractures: the use of angiography in controlling arterial hemorrhage. *J Trauma*. 2007 Jun. 62(6 Suppl):S30-1.
3. Poole GV, Ward EF, Muakkassa FF. Pelvic fracture from major blunt trauma. Outcome is determined by associated injuries. *Ann Surg*. 1991 Jun. 213(6):532-8; discussion 538-9.
4. Dalal SA, Burgess AR, Siegel JH, et al: Pelvic fracture in multiple trauma: Classification by mechanism is key to pattern of organ injury, resuscitative requirements, and outcome. *J Trauma* 1989;29:981-1002.
5. McMurtry R, Walton D, Dickinson D, Kellam J, Tile M: Pelvic disruption in the polytraumatized patient: A management protocol. *Clin Orthop Relat Res* 1980; 151:22-30.
6. Bosch U, Pohlemann T, Haas N, Tscherne H: Classification and management of complex pelvic trauma [German]. *Unfallchirurg* 1992;95:189- 196.
7. Oh JS, Tubb CC, Poepping TP, Ryan P, Clasper JC, Katschke AR, Tuman C, Murray MJ. Dismounted blast injuries in patients treated at a Role 3 military hospital in Afghanistan: Patterns of injury and mortality. *Mil Med*. 2016 Sep;181(9):1069-74.
8. Smith WR, Williams A, Agudelo J, et al. Early predictors of mortality in hemodynamically unstable pelvis fractures. *J Orthop Trauma* 2007;21:31-37.
9. Osborn PM, Smith WR, Moore EE, et al. Direct retroperitoneal pelvic packing versus pelvic angiography: a comparison of two management protocols for haemodynamically unstable pelvic fractures. *Injury* 2009;40:54-60.
10. Roszman AD, John DQ, Patch DA, Spitler CA, Johnson JP. Management of open pelvic ring injuries. *Injury*. 2023 Apr;54(4):1041-1046.
11. Shackelford SA, Hammesfahr R, Morissette DM, et al. The use of pelvic binders in Tactical Combat Casualty Care: TCCC Guidelines Change 1602 7 November 2016. *J Spec Oper Med*. 2017 Spring;17(1):135-147.
12. Pierrie SN, Seymour RB, Wally MK, Studnek J, Infinger A, Hsu JR; Evidence-based Musculoskeletal Injury and Trauma Collaborative (EMIT). Pilot randomized trial of pre-hospital advanced therapies for the control of hemorrhage (PATCH) using pelvic binders. *Am J Emerg Med*. 2021 Apr;42:43-48.

13. Coccolini F, Stahel PF, Montori G, et al. Pelvic trauma: WSES classification and guidelines. *World J Emerg Surg.* 2017 Jan 18;12:5.
14. Routt CML Jr, Falicov A, Woodhouse E, Schildhauer TA. Circumferential pelvic antishock sheeting: a temporary resuscitation aid. *Journal of Orthopaedic Trauma* 16(1):p 45-48, January 2002.
15. Swartz J, Vaidya R, Hudson I, Oliphant B, Tonnos F. Effect of pelvic binder placement on OTA classification of pelvic ring injuries using computed tomography. does it mask the injury? *J Orthop Trauma.* 2016 Jun;30(6):325-30.
16. Fagg JAC, Acharya MR, Chesser TJS, Ward AJ. The value of 'binder-off' imaging to identify occult and unexpected pelvic ring injuries. *Injury.* 2018 Feb;49(2):284-289.
17. Baker JE, Werner NL, Burlew CC. Management of pelvic trauma. *Surg Clin North Am.* 2024 Apr;104(2):367-384.
18. Smith WR, Moore EE, Osborn P, et al. Retroperitoneal packing as a resuscitation technique for hemodynamically unstable patients with pelvic fractures: report of two representative cases and a description of technique. *J Trauma* 2005 Dec;59(6):1510-4

## ADDITIONAL REFERENCES

1. Mucha P Jr, Farnell MB: Analysis of pelvic fracture management. *J Trauma* 1984;24:379-386.
2. Smith W, Williams A, Agudelo J, et al. Early predictors of mortality in hemodynamically unstable pelvis fractures. *J Orthop Trauma.* 2007;21(1):31-37.
3. Davis JM, Stinner DJ, Bailey JR, Aden JK, Hsu JR and the STREC Consortium investigators. Factors associated with mortality in combat-related pelvic fractures. *J Am Acad Orthop Surg* 2012; 20(suppl 1):S7-S12
4. Ben-Menachem Y, Coldwell DM, Young JW, Burgess AR: Hemorrhage associated with pelvic fractures: Causes, diagnosis, and emergent management. *AJR Am J Roentgenol* 1991;157:1005-1014.
5. Hak D, Smith W, Suzuki T. Management of hemorrhage in life-threatening pelvic fracture. *J Am Acad Orthop Surg.* 2009;17:447-4
6. DuBose J, Inaba K, Barmparas G, et al. Bilateral internal iliac artery ligation as a damage control approach in massive retroperitoneal bleeding after pelvic fracture. *J Trauma.* 2010 Dec;69(6):1507-14.
7. Biffl W, Smith W, Moore E, et al. Evolution of a Multidisciplinary Clinical Pathway for the Management of Unstable Patients with Pelvic Fractures. *Annals of Surgery.* 2001;233(6):843-850.
8. Parker WJ, Despain RW, Delgado A, et al. Pelvic Binder Utilization in Combat Casualties: Does It Matter? *Am Surg.* 2020 Jul;86(7):873-877.
9. Watkins RJ, Hsu JM. The Road to Survival for Haemodynamically Unstable Patients With Open Pelvic Fractures. *Front Surg.* 2020 Sep 2;7:58.
10. Williamson F, Coulthard LG, Hacking C, Martin-Dines P. Identifying risk factors for suboptimal pelvic binder placement in major trauma. *Injury.* 2020 Apr;51(4):971-977.
11. Costantini TW, Coimbra R, Holcomb JB, et al. Pelvic fracture pattern predicts the need for hemorrhage control intervention-Results of an AAST multi-institutional study. *J Trauma Acute Care Surg.* 2017 Jun;82(6):1030-1038.
12. White CE, Hsu, JR, Holcomb JB. Haemodynamically unstable pelvic fractures. *Injury* 2009.
13. Cothren CC, Osborn PM, Moore EE, et al. Preperitoneal pelvic packing for hemodynamically unstable pelvic fractures: a paradigm shift. *J Trauma* 2007;62:834.
14. Martinelli T, Thony F, Declety P, et al. Intra-aortic balloon occlusion to salvage patients with life-threatening hemorrhagic shock from pelvic fractures. *J Trauma.* 2010;68:942-948.

## APPENDIX A: PELVIC FRACTURE CLINICAL PATHWAY



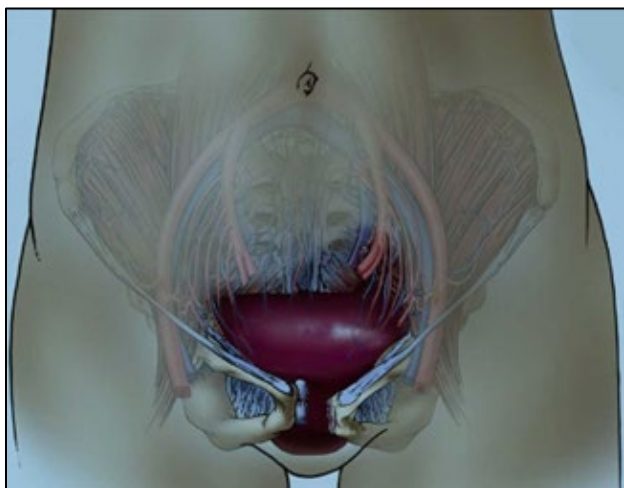
---

## APPENDIX B: PELVIC PACKING TECHNIQUE

---

1. Clinical Indications
  - a. Persistent hypotension (SBP <90) despite resuscitation and stabilization of unstable pelvic fracture
2. Key Anatomy
  - a. Pre-peritoneal space: Space of Retzius
  - b. Peritoneal space: abdominal cavity
  - c. Retroperitoneal space: space posterior to peritoneum
  - d. Venus plexus along anterior sacrum
  - e. Large potential space for hemorrhage in the pre and retroperitoneal space

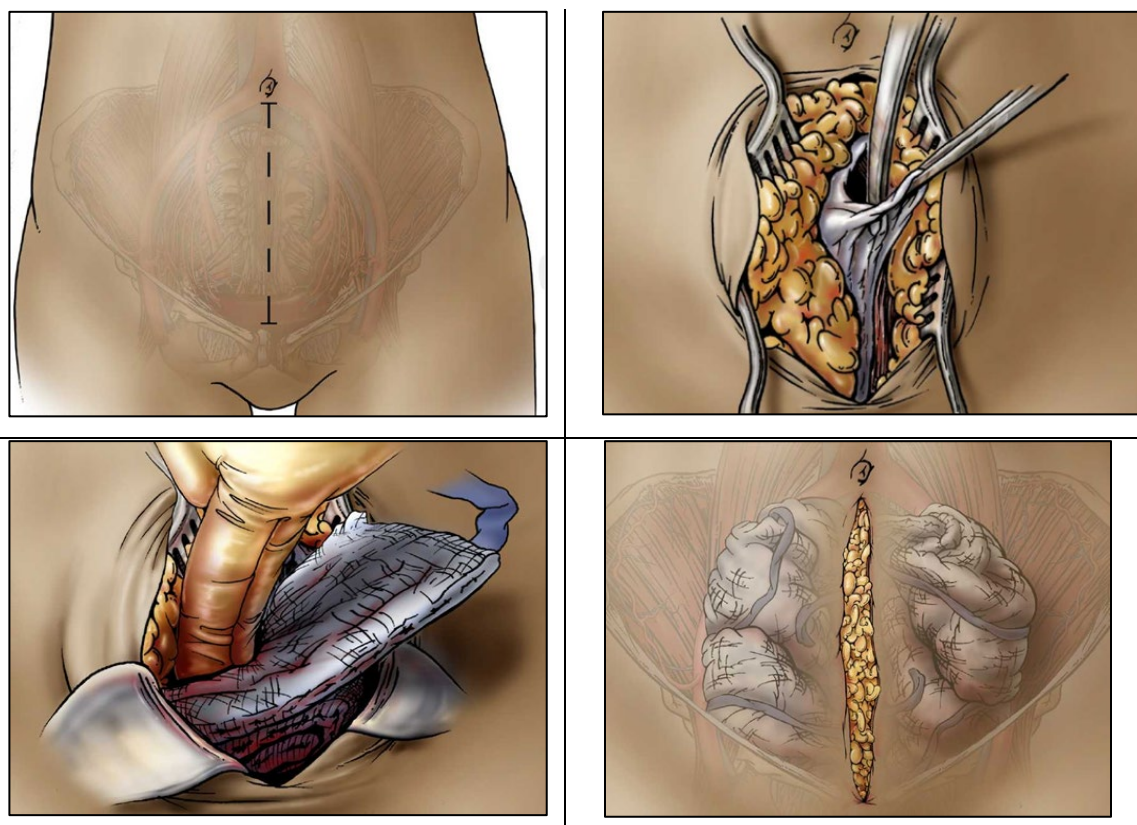
**Figure 1. Pelvic ring injury can result in a large potential space for hemorrhage in the pre-peritoneal space.**



**Source: Combat Orthopaedic Trauma Surgery Course (COTS+)**

3. Steps
  - a. Make a longitudinal low, vertical midline incision between the umbilicus and pubis.
  - b. Divide the rectus sheath along the linea, to enter the pre-peritoneal space (Space of Retzius), taking care to avoid entering the peritoneal space
  - c. Evacuate pelvic hematoma if present.
  - d. Place 3-4 packs on each side of the retroperitoneal space to tamponade bleeding. Place the packs posteriorly and deep.
  - e. Close fascia or skin over the packs.
4. Pearls/Pitfalls
  - a. Do not place packs intra-peritoneal, this will not tamponade the targeted bleeding.
  - b. Ensure packs are rolled so you can more effectively roll them posteriorly into the retroperitoneal space.
  - c. Be sure to also stabilize the pelvis with a sheet/binder or external fixator.

**Figure 2.** Illustrated steps of pelvic packing as described in text.



Source: COTS+

---

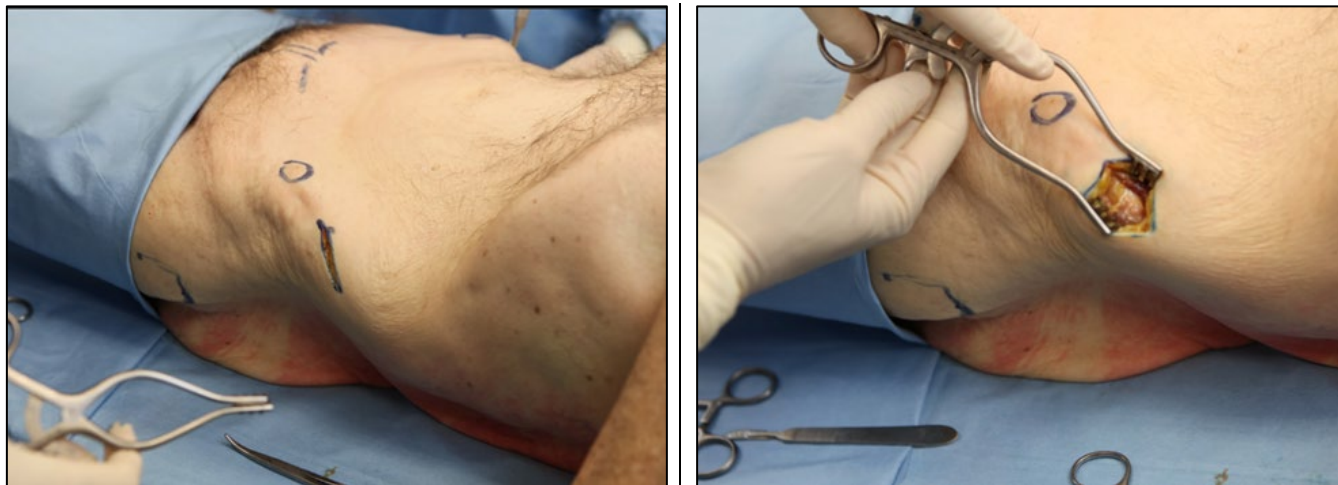
## APPENDIX C: PELVIC STABILIZATION TECHNIQUE

---

### External Fixation of the Pelvis (Iliac Crest Technique)

1. Clinical Indications
  - a. Unstable pelvis fracture not amenable temporizing stabilization with pelvic sheet or binder
  - b. Temporizing stability of proximal femur fractures that require pelvic pins given their location
  - c. Significant perineal or rectal wounds that preclude use of a binder
2. Damage control surgery without fluoroscopy. If fluoroscopy is available, and the surgical team is appropriately trained and comfortable with this technique, supra-acetabular pins should be placed under radiographic guidance.
3. Key Anatomy
  - a. Anatomic landmark for safe pin placement using the Iliac Crest Technique is two fingerbreadths posterior to the anterior superior iliac spine (ASIS) which is palpable in nearly everyone.
4. Steps
  - a. Mark an incision approximately two fingerbreadths posterior to the ASIS along the iliac crest.
  - b. Sharply dissect down to expose the iliac crest. You may dissect soft tissues off to expose inner and outer tables of the iliac crest.

**Figure 1.** Incision placed two fingerbreadths posterior to ASIS along the iliac crest.

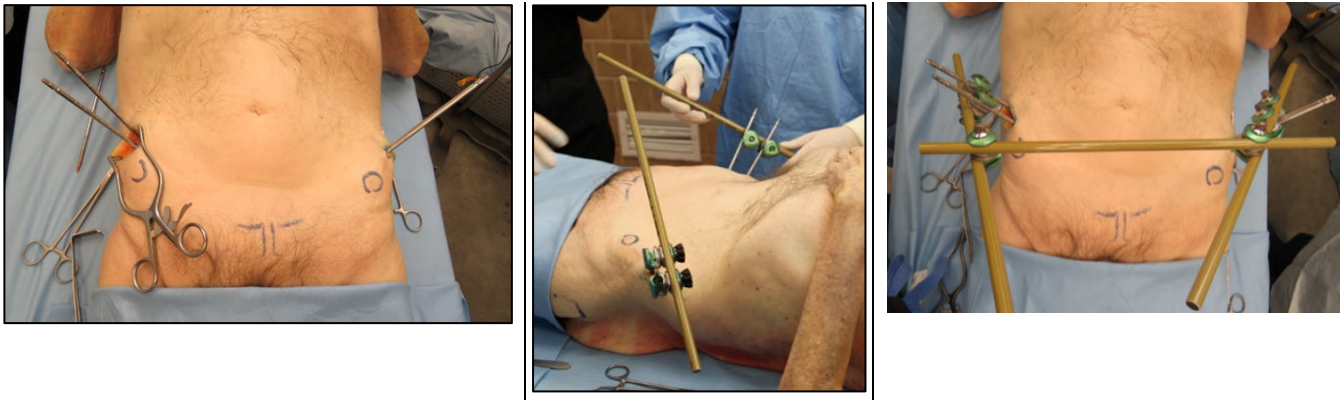


**Source:** COTS+

- c. Place first pin two fingerbreadths posterior to ASIS and place second one posterior to that.
  - d. Repeat the same steps on the contralateral hemipelvis.
  - e. Assemble frame and manipulate pelvis to achieve a closed reduction prior to tightening the frame.



**Figure 2.** Two pins are placed in each iliac crest, followed by frame assembly, pelvis reduction, and tightening of all clamps.

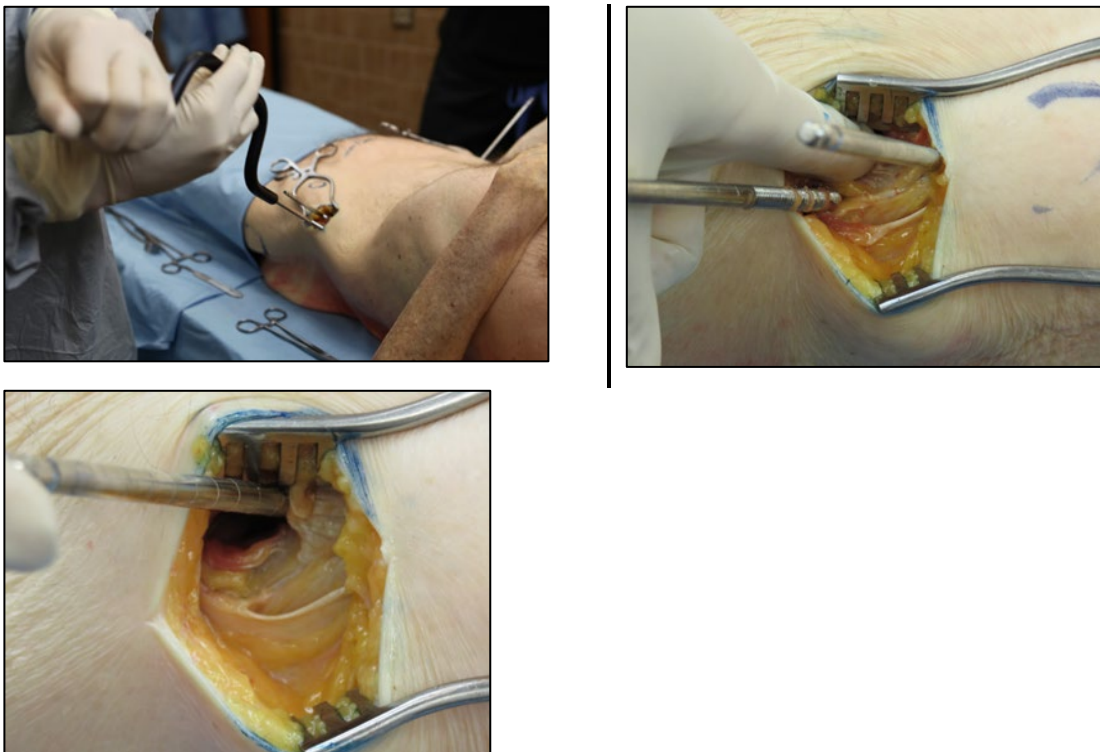


**Source:** COTS+

5. Pearls/Pitfalls

- a. There are several tricks that can be used to ensure appropriate trajectory of iliac crest pins:
  - i. Aim towards the contralateral greater trochanter
  - ii. Place a second pin resting along the inner table of the pelvis to help demarcate the slope of the iliac crest.
  - iii. Dissect soft tissues off the inner and outer table. Place thumb and index finger around the crest. Aim the pin in that trajectory to ensure it is staying within the narrow corridor of bone.

**Figure 3.** Use additional pin or fingers to palpate ilium and guide trajectory of pin between inner and outer tables of the ilium.



**Source:** COTS+

## APPENDIX D: CLASS VIII MEDICAL MATERIEL

Detailed overview of the essential medical materiel required for adequate pelvic fracture care, according to the Joint Trauma System (JTS) Clinical Practice Guidelines.

### PELVIC STABILIZATION DEVICES

- Pelvic binder or sheet wrap

### HEMORRHAGE CONTROL & RESUSCITATION SUPPLIES

- IV fluids, including crystalloids, and blood products (RBCs, plasma, platelets, whole blood) per damage control resuscitation protocols.
- Sterile surgical packs containing sponges and instruments for packing the preperitoneal space to control bleeding.
- Tranexamic acid (TXA).

### IMAGING & DIAGNOSTIC RESOURCES

- Portable X-ray machine.
- Portable ultrasound (FAST) capabilities.
- Access to CT imaging with contrast (Role 3+ environments).

### SURGICAL & ORTHOPEDIC EQUIPMENT

- External fixation sets – either temporary or definitive, including fixator frames and pins.
- Orthopedic instrument set – including bone saws, drill guides, traction devices.
- Suture materials – heavy and fine sutures (PDS, Prolene), vessel loops, pledgets for soft tissue repair.
- Topical hemostatic agents and ample surgical sponges.

### RESUSCITATIVE & CRITICAL CARE SUPPORT

- Airway management equipment – BVMs, ET tubes, video laryngoscopes.
- Portable monitors – pulse oximetry, ETCO<sub>2</sub>, Pressure lines (A-line, CVP) NIBP equipment.
- Blood warming/infusion devices – e.g., Belmont rapid infuser or in-line warmers.
- REBOA catheter kits if endovascular hemorrhage control is indicated.

### MEDICATIONS & ANCILLARY SUPPLIES

- Analgesics and anesthetics, both IV and oral.
- Antibiotics, including broad-spectrum agents for open fractures.
- IV calcium, ACLS medications, and antiepileptics.

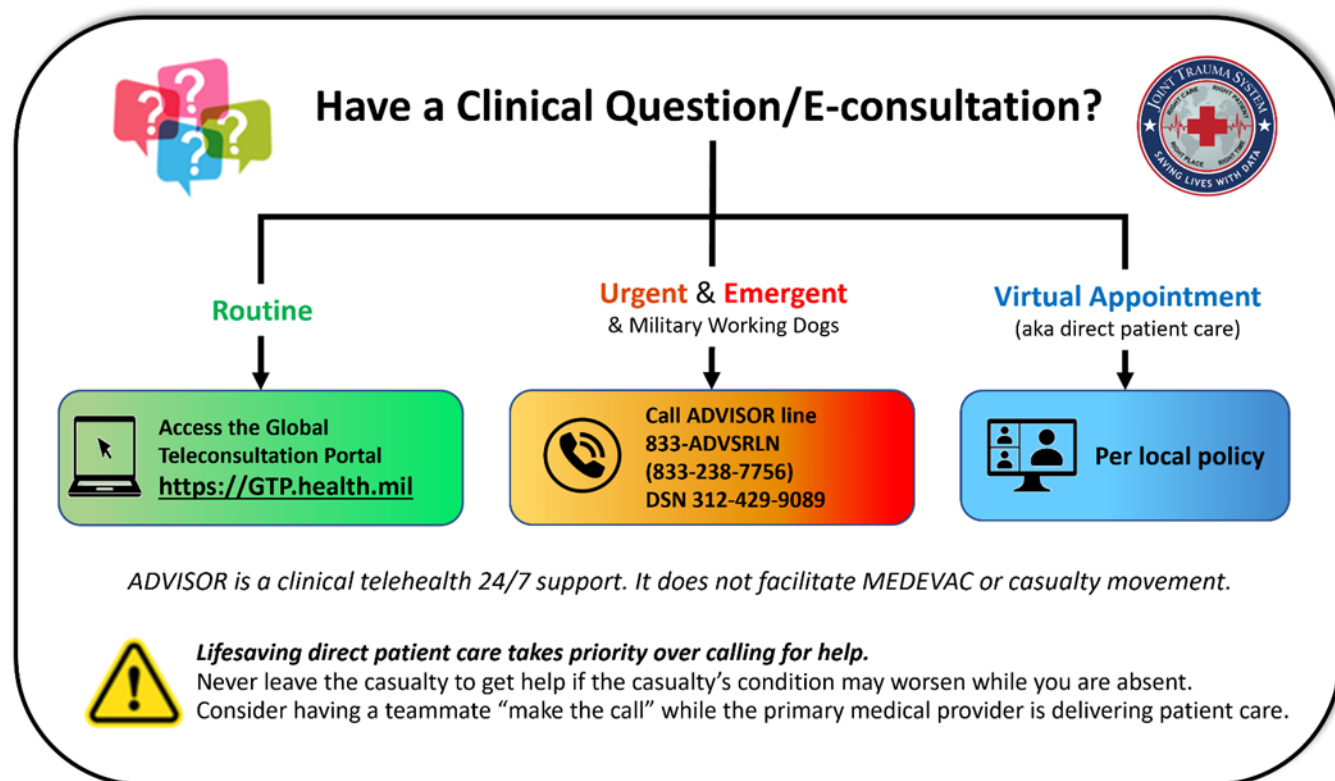
### POSTOPERATIVE CARE

- Wound Care Supplies: Dressings, antiseptics, and bandages for postoperative wound management.
- Deep Vein Thrombosis (DVT) Prophylaxis Equipment: Compression devices and anticoagulant medications to prevent blood clots.

For additional information including National Stock Number (NSN), please contact: [dha.ncr.med-log.list.lpr-cps@health.mil](mailto:dha.ncr.med-log.list.lpr-cps@health.mil)

**DISCLAIMER:** This is not an exhaustive list. These are items identified to be important for the care of combat casualties.

## APPENDIX E: TELEMEDICINE / TELECONSULTATION



*Illustration by Raymond Samonte*

GTP: <https://GTP.health.mil>

Theater Patient Movement Requirements Center (TPMRC) to coordinate evacuation:

- TPMRC-Americas (NORTHCOM & SOUTHCOM), 618-817-4200
- TPMRC- East (EUCOM, AFRICOM, CENTCOM), DSN 314-480-8040
- TPMRC- West (INDOPACOM), DSN 315-448-1062

---

## APPENDIX F: INFORMATION REGARDING OFF-LABEL USES IN CPGS

---

### PURPOSE

The purpose of this Appendix is to ensure an understanding of DoD policy and practice regarding inclusion in CPGs of “off-label” uses of U.S. Food and Drug Administration (FDA)–approved products. This applies to off-label uses with patients who are armed forces members.

### BACKGROUND

Unapproved (i.e., “off-label”) uses of FDA-approved products are extremely common in American medicine and are usually not subject to any special regulations. However, under Federal law, in some circumstances, unapproved uses of approved drugs are subject to FDA regulations governing “investigational new drugs.” These circumstances include such uses as part of clinical trials, and in the military context, command required, unapproved uses. Some command requested unapproved uses may also be subject to special regulations.

### ADDITIONAL INFORMATION REGARDING OFF-LABEL USES IN CPGS

The inclusion in CPGs of off-label uses is not a clinical trial, nor is it a command request or requirement. Further, it does not imply that the Military Health System requires that use by DoD health care practitioners or considers it to be the “standard of care.” Rather, the inclusion in CPGs of off-label uses is to inform the clinical judgment of the responsible health care practitioner by providing information regarding potential risks and benefits of treatment alternatives. The decision is for the clinical judgment of the responsible health care practitioner within the practitioner-patient relationship.

### ADDITIONAL PROCEDURES

#### Balanced Discussion

Consistent with this purpose, CPG discussions of off-label uses specifically state that they are uses not approved by the FDA. Further, such discussions are balanced in the presentation of appropriate clinical study data, including any such data that suggest caution in the use of the product and specifically including any FDA-issued warnings.

#### Quality Assurance Monitoring

With respect to such off-label uses, DoD procedure is to maintain a regular system of quality assurance monitoring of outcomes and known potential adverse events. For this reason, the importance of accurate clinical records is underscored.

#### Information to Patients

Good clinical practice includes the provision of appropriate information to patients. Each CPG discussing an unusual off-label use will address the issue of information to patients. When practicable, consideration will be given to including in an appendix an appropriate information sheet for distribution to patients, whether before or after use of the product. Information to patients should address in plain language: a) that the use is not approved by the FDA; b) the reasons why a DoD health care practitioner would decide to use the product for this purpose; and c) the potential risks associated with such use.