

JOINT TRAUMA SYSTEM CLINICAL PRACTICE GUIDELINE (JTS CPG)



Cervical and Thoracolumbar Spine Injury Evaluation, Transport, and Surgery in the Deployed Setting (CPG ID: 15)

Guidance for providing the best care to patients who suffer a spine or spinal cord injury.

Contributors

CDR Chris Neal, MC, USN
Col Randall McCafferty, USAF, MC
LTC Brett Freedman, MC, USA
MAJ Melvin Helgeson, MC, USA

COL Michael Rosner, MC, USA
Dennis Rivet, MD
CDR David Gwinn, MC, USN

First Publication Date: 01 Jul 2010

Publication Date: 05 Aug 2016

Supersedes CPG dated 09 Mar 2010

TABLE OF CONTENTS

Goal	3
Background.....	3
Evaluation.....	3
Neurologic Exam	3
Patients Who Need a Rigid Cervical Collar	4
Indications for Cervical Spine Clearance Algorithms	5
Cervical Spine Clearance in the Obtunded Patient.....	5
Cervical Spine Clearance Documentation	6
Transporting Patients with Spinal Injuries.....	6
Medical Management of Spinal Cord Injuries	6
Handling	7
Corticosteroids	7
DVT Prophylaxis Regimen	7
Operative and Nonoperative Treatment of Spinal Injuries	7
Penetrating Spine Injuries	8
Surgical Intervention.....	8
Treatment	9
Performance Improvement (PI) Monitoring	9
Intent (Expected Outcomes)	9
Performance/Adherence Measures.....	9
Data Source.....	10
System Reporting & Frequency.....	10
Responsibilities.....	10
References.....	10
Appendix A: American Spinal Injury Association (ASIA) Worksheet	13

Appendix B: Combat Neuro Exam Worksheet.....	15
Appendix C: Cervical Spine Clearance Algorithm Reliable Patient with no Neurologic Deficit	17
Appendix D: Cervical Spine Clearance Algorithm Unreliable Patient	18
Appendix E Cervical Spine Clearance Status.....	19
Appendix F: Additional Information Regarding Off-label Uses in CPGs	20

GOAL

The goal of the Cervical and Thoracolumbar Spine Injury Evaluation, Transport, and Surgery CPG is to deliver updated, accurate guidance to the deployed provider in order to provide the best care to patients who suffer a spine or spinal cord injury. This requires constant re-evaluation of the literature, both military and civilian, in addition to reviewing the lessons learned from past and present deployments. This involves not only changes in treatment and triage algorithms, but also updates on injury classification and current mechanisms of injury being seen.

BACKGROUND

As an overview, Blair et al published a review of spine injuries as noted in the Department of Defense Trauma Registry (DoDTR) from October 2001 to December 2009. They discovered 502 service members that sustained 1,834 different battle injuries to the spinal column compared to 92 service members that sustained 267 non-battle spine injuries. Of the battle injured, 91 had spinal cord injuries, of which 45% were complete. This compares to the 12 non-battle spinal cord injuries, of which 46% were complete. Within the battle injured, the mechanism of injury was classified as an explosive injury in 66.7%, gunshot wound in 17% and falls in 3%.¹ In the same journal, Blair et al evaluated penetrating versus blunt spine injuries documented in the DoDTR. They found 598 service members with injuries to the spine or spinal cord. Of this group, the mechanism was blunt trauma in 66%, penetrating in 28%, and combined blunt and penetrating in 5%. Of this cohort, 104 (17%) suffered a spinal cord injury, with spinal cord injuries occurring in 10% of those with blunt mechanism of injury and 38% in penetrating injuries.²

The timing and location of surgical intervention has also been a point of debate both in civilian and military settings.³⁻⁵ The paucity of data defining the optimal setting for surgical intervention when the injury occurs in a combat zone adds further challenges. The goal of decompressing and stabilizing the spine/spinal cord injury must be weighed by operational and logistical considerations, in addition to the ability of the deployed spine surgeon.

In general, spine trauma patients may be placed into one of three clinical categories: Patients with complete spinal cord syndromes; Patients with an incomplete spinal cord injury; Patients with a spine fracture but normal neurological function. In regards to the timing of surgery, an incomplete injury from a non-penetrating mechanism is often the most problematic in the decision-making process.

EVALUATION

NEUROLOGIC EXAM

Every effort must be made to document an accurate and thorough neurological examination, especially when surgery or aeromedical transport is planned.⁶ The quality of the examination can be degraded by medicines, presence of an airway adjunct or endotracheal tube, cardiovascular and pulmonary performance, and presence of other injuries to the head, torso or extremities. Failure to perform and document a neurological exam has been the most common source of discrepancy between serial neurological examination findings, especially between levels of care.

A thorough neurologic exam should include:

- Motor exam of the 10 American Spinal Injury Association (ASIA) key motor groups ([Appendix A](#))
- Sensory examination (pin prick and light touch) using ASIA dermatomal standards
- Digital rectal exam that assesses voluntary anal sphincter contraction strength, pinprick sensation, resting tone and bulbocavernosus reflex (BCR).

- Normal and pathological reflex testing such as biceps, triceps, brachioradialis, knee, and ankle jerk responses as well as presence/absence of Babinski reflex.

In patients with suspected spinal column injury, with or without neurologic deficit upon presentation, frequent repetition and surveillance of the neurologic examination (focusing upon motor and sensory performance) is imperative. It is recommended to use [Appendix A: ASIA Worksheet](#) and attach to the patient's chart.

Alternatively, the "Combat Neuro Exam" is a simpler documentation tool than the ASIA Worksheet and may be more amenable to non-spine specialists to complete. (See [Appendix B: Combat Neuro Exam](#).) This note addresses the minimal elements of a complete neurological exam for a patient with significant spinal column injury. Fill out and attach to the patient's chart.

PATIENTS WHO NEED A RIGID CERVICAL COLLAR

All patients who have sustained injuries through the following mechanisms should have a rigid cervical collar placed in the pre-hospital environment if the tactical situation allows:

- Trauma resulting in loss of consciousness or even the question of loss of consciousness due to any form of head injury.
- Trauma resulting in temporary amnesia/loss of consciousness.
- Major explosive or blast injury.
- Mechanism that produces a violent impact on the head, neck, torso or pelvis.
- Mechanism that creates sudden acceleration/deceleration or lateral bending forces on the neck or torso.
- Fall from height (vs. fall from standing).
- Ejection or fall from any motorized vehicle.
- Vehicle roll-over.

Any patient complaining of neck pain or displaying neurological impairment following a trauma should have a cervical collar placed and maintained until the cervical spine has been "cleared" by a qualified provider.^{6,7}

Patients with penetrating cervical injury from an explosive mechanism should have a cervical collar placed if possible. When a blunt mechanism is combined with a penetrating injury, the cervical collar is an important protection until an unstable spinal injury is ruled out. All providers must be aware that the collar may hide other injuries as well as and developing pathology such as expanding hematoma. Patients with isolated penetrating cervical injury who are conscious and have no neurologic signs should not have a cervical collar placed in the pre-hospital environment. Patients with isolated penetrating brain injury do not require a cervical collar unless the trajectory suggests cervical spine involvement.⁸ On the battlefield, preservation of the life of the casualty and medic are of paramount importance. In these circumstances, evacuation to a more secure area takes precedence over spine immobilization.

If a patient has indications for cervical collar placement, and one had not been placed in the pre-hospital environment for whatever reason, the collar should be placed at the earliest opportunity. At each transition in care from downrange, unless cervical clearance has been clearly documented in the record or directly communicated to the accepting treatment team, a rigid cervical collar should be placed and maintained until it is officially cleared by the accepting providers. This highlights the need for clear and consistent communication along the echelons of care.

INDICATIONS FOR CERVICAL SPINE CLEARANCE ALGORITHMS

Any patient with a suspected cervical spine injury and a neurologic deficit should have a cervical collar in place, and should be referred immediately for neurosurgical or orthopedic spine consultation and imaging. All other patients who have indications for pre-hospital cervical collar placement as detailed above should undergo cervical spine clearance by algorithm. There are separate algorithms for reliable ([Appendix C](#)) and unreliable ([Appendix D](#)) patients. Unreliable patients are those who cannot adequately communicate, have a decreased level of consciousness (GCS<15), or have a significant distracting injury.

Significant distracting injury is defined as any injury, which is so painful that it may obscure the patient's ability to notice pain in their neck. The treating physician has final say in determining if a certain injury is distracting enough to render a patient unreliable and require clearance via the unreliable patient algorithm. If uncertain, err on the side of caution and consider the injury distracting and proceed accordingly.

See [Appendix C](#) and [Appendix D](#) for protocol diagrams. If possible, the cervical spine should be cleared and the collar removed within 24 hours of collar placement. If the clinical scenario requires the collar remain in place more than 24 hours, stiff extrication collars should be replaced with collars designed for long-term immobilization that provide greater padding and decubitus ulcer prevention.

CERVICAL SPINE CLEARANCE IN THE OBTUNDED PATIENT

Cervical spine clearance in the obtunded patient presents additional challenges to the clinician, especially in the combat environment.^{6,8,9} Obtunded patients with a concerning mechanism of injury should undergo CT of the spine with fine cuts and multi-planar reconstructed images (3 mm axial, 3 mm coronal and 2 mm sagittal views). If CT is unavailable or unobtainable, full C-Spine plain radiographs (adequate AP, lateral and odontoid) should be performed.

For the obtunded patient with negative imaging, the incidence of significant cervical instability is small but it is not zero. Occult ligamentous injury is only cleared through a reliable clinical examination with a cooperative, extubated patient or magnetic resonance imaging (MRI). However, recent literature suggest that a high quality negative CT scan may be enough to remove the cervical collar.¹⁰ This has become the new standard to follow in several high level acute civilian trauma centers and supports the guideline to forgo an MRI as a requirement to clear an obtunded patient. This method of clearance should be reserved for those patients who cannot undergo an MRI and have arrived at their definitive level of care. Flexion/extension radiography should not be performed in a patient who cannot be simultaneously examined for the development of neurological signs or symptoms.

The clinical decision to definitively clear the cervical spine without exclusion of ligamentous injury by either a reliable clinical examination or a MRI should be left to the level of care providing definitive treatment to the patient. There is risk for significant neck movements in obtunded patients while transiting through the aeromedical evacuation system, so it is recommended that they remain with cervical spine immobilization until arrival at their definitive level of care. The incidence of occipital skin breakdown has decreased with the utilization of collars with greater padding (e.g., Miami-J with Occian back) and increased trauma system awareness of this potential complication. Given the challenges and multiple hand-offs inherent to echeloned care, it may be best to apply a "2 out of 3" rule for cervical clearance in the obtunded patient. This rule, which has been developed and validated in the civilian sector and has been Landstuhl Regional Medical Center/Role 4 policy since 2011, requires negative results of 2 of 3 modalities (CT, MRI, clinical exam) prior to removing rigid cervical collars in obtunded patients. Given the low, but non-zero, incidence of significant cervical injury missed on standard 3-plane CT scan, it is recommended that when applying the 2 out of 3 rule, that the obtunded patient be transitioned from the traditional rigid collars to a memory foam enhanced rigid collar if available (i.e. Miami-J with Occian back) until either a reliable clinical examination or MRI can be obtained.¹⁰⁻¹⁴ This method helps to decrease the risk of an occipital decubitus ulcer in those patients with a low likelihood of cervical spine injury that are still in transport and have not yet arrived at their level of definitive care.

Determination of when to image the whole spine (occiput to sacrum) versus selective imaging is based on the mechanism of injury, the physical/neurological exam, as well as the mental status of the patient. Patients who have one identifiable fracture in the spine should have their entire spine imaged. Certain mechanisms of injury, such as a mounted blast, should also warrant imaging of the whole spine.

CERVICAL SPINE CLEARANCE DOCUMENTATION

It is required that the JTS Cervical Spine Clearance Status Sheet ([Appendix E](#)) or Trauma Resuscitation Record (DD Form 3019) be used for documenting the cervical spine evaluation and clearance status. This comprehensive note includes indications for clearance, exam, imaging studies, and final clearance status. The note is intended to bring together all cervical spine information onto one sheet of paper and was designed to improve both the completeness and ease of documentation.

HOST NATIONALS AND THOSE UNABLE TO TRANSFER FROM THEATER

The optimal management of this group is problematic in the austere environment. The availability to obtain CT or transfer the patient to a facility with CT can make spine evaluation and clearance challenging, with reliance on plain radiographs and physical examination. Sound clinical judgment and remote consultation with a spine surgeon (if available) are of benefit.

TRANSPORTING PATIENTS WITH SPINAL INJURIES

The majority of patients with cervical spine injuries will be transported using semi-rigid orthotic such as an Aspen collar. Clinical scenarios may arise wherein halo immobilization may be suitable. Transporting patients in traction is a logistically challenging option given the dynamics of air transport, particularly G-Forces during aircraft takeoff and landing, and the multiple transfers required from hospital to vehicle to aircraft to vehicle to hospital.

If the patient has a thoracolumbar fracture that is unstable, then he/she should be transported by the Critical Care Air Transport Team (CCATT) using either a vacuum spine board (VSB) or a standard NATO litter with or without a memory foam pad, depending on the type of fracture. Depending on the injury, either of these options can provide sufficient stability to patients with thoracolumbar fractures.¹⁵

A thoracolumbosacral orthosis (TLSO) or other external brace should not be worn during the transport process. This is unnecessary and increases the risk of pressure sores. Prior to transport, the spine surgeon and CCATT leader should agree upon suitability of VSB versus standard NATO litter. The VSB protocol requires that the VSB be deflated and re-inflated periodically to reduce the risk of pressure sores during the transport process. Logrolling in a VSB without “release of vacuum” does not significantly reduce skin pressure. Additionally, pre-transported skin integrity should be documented and care must be given to padding and pressure reduction maneuvers of the occiput and heels. Once cruising in smooth flight is accomplished, it would be reasonable to release the vacuum until either descent or turbulence is encountered. At a minimum, the VSB pressure should be checked every half hour, smoothed and re-pressurized every hour, and every two hours the team should release straps and logroll patient (holding patient in appropriate alignment) and provide adequate time for relief of pressure points as part of their normal turning schedule. The head of the bed should be elevated 30 degrees unless specifically told otherwise by the spine surgeon. During transport, all patients should use the sequential compression devices, which are approved for flight.

MEDICAL MANAGEMENT OF SPINAL CORD INJURIES

Patients who sustain neurologic compromise should have an invasive arterial line for continuous blood pressure monitoring with a goal MAP of 85-90 mm Hg for up to seven days following the injury.⁶ Hypotension (SBP < 90 mm Hg) and hypoxemia (SaO₂ < 92%) must be avoided. Vasopressor therapy (in the euvolemic patient) and/or

supplemental oxygen are recommended, when necessary, to achieve these goals.⁶ Vasopressor use in the hypovolemic patient may contribute to additional ischemic loss in other injured tissues, so fluids remain the initial therapy for hypotension.

HANDLING

While many spinal fractures require the head of bed to be flat prior to surgical correction or external bracing, the bed can usually be placed in 30 degrees reverse Trendelenberg. Logrolling the patient can be safely performed in most cases every 2 hours to prevent skin breakdown. It is incumbent upon the spine surgeon to alter these assumptions based upon the specific clinical scenario.

CORTICOSTEROIDS

The use of corticosteroids in the setting of either blunt or penetrating spinal cord injury is not recommended due to the lack of benefit and increased complications.⁶ Furthermore, the associated open or contaminated wounds of battle casualties with spine or spinal cord injuries further complicate steroid administration. Methylprednisolone administration is not recommended for any spinal cord injuries sustained in combat.

DVT PROPHYLAXIS REGIMEN

An aggressive deep vein thrombosis (DVT) prophylaxis regimen should be established early and maintained beyond the evacuation process. Pneumatic compression devices in conjunction with chemoprophylaxis are established treatment standards. Prophylactic dosing of a subcutaneous low molecular weight heparin (LMWH -- e.g. enoxaparin) is preferred and can usually be initiated within 24-72 hours of injury or repair. Early active or passive mobilization of the patient helps to reduce DVT formation and is frequently cited in support of early surgical fixation, when appropriate. Patients who show clinical signs or symptoms of a DVT should undergo further imaging to confirm the diagnosis. If a DVT is present, treatment should be initiated with therapeutic anticoagulation if approved by the spine surgeon. If full anticoagulation is contraindicated, an IVC filter placement should be considered.

OPERATIVE & NONOPERATIVE TREATMENT OF SPINAL INJURIES

External immobilization options for the cervical spine in theater should include semi rigid cervical orthosis (e.g., Aspen collar), halo, and sternal-occipital-mandibular immobilizer (SOMI)-like devices or cervico-thoracic braces (e.g. Aspen CTO). Aspen TLSO and LSO devices may also be available at certain Role 3 facilities for bracing of thoracolumbar injuries and are primarily suitable for use on patients with stable injuries for which TLSO will be definitive treatment. The actual materials on hand in the deployed setting may be variable. It is imperative that the deployed spine surgeon be intimately familiar with the immediate availability and serviceability of these devices in the assigned expeditionary medical treatment facility in order to proactively guide treatment and logistical decisions.

The operative treatment of US and coalition spine fractures in theater is ultimately left to the deployed surgical team, to include the spine surgeon and the Chief of Trauma. It cannot be over emphasized that the use of good clinical judgment is a priority in the care of patients with spine and spinal cord injuries in a deployed setting. Surgery that can be delayed safely until the patient arrives to the Role 4 or 5 military treatment facility should be delayed. However, there may be some patients who would benefit from immediate surgery in-theater (when available) and these include patients with incomplete injuries, open CSF leak, an expected prolonged delay in transport, or where an urgent reduction may improve the degree of "root sparing" in a cervical spinal cord injury.^{16,17}

Given the absence of Level 1 or 2 evidence guiding the ideal timing for spinal decompression and stabilization of combat-related spine injuries, we are left to rely on retrospective experience and abstraction from animal and

civilian clinical studies. The most concerning subset of spine injured patients are those with incomplete injuries. Progressive spinal cord injury can occur via fracture displacement, bone fragment compression, expanding hematoma, spinal cord edema, or infarction. Animal studies have demonstrated that immediate decompression of neural elements is associated with a reduction in permanent neurological sequela.^{18, 19} Furthermore, data from the STASCIS trial offers compelling evidence in favor of early surgery.⁵ This large, multi-center, prospective study showed that neurological outcomes improved at least 2 ASIA grades in 19.8% of spinal cord injured patients undergoing early decompression (<24 hours) versus 8.8% undergoing late decompression (>24 hours) and that early decompression was at least as safe as late decompression. A recent review of the Rick Hansen National Spinal Cord Injury Registry encompassing 949 patients from 2004-2013 showed that patients with incomplete injury (ASIA B, C, or D) had a 6.3 point improvement in ASIA motor scores when decompressed within 24 hours compared to those operated on after 24 hours from injury. This suggests that early surgery is beneficial for incomplete spinal cord injuries.²⁰ Ultimately, the decision to operate on an incomplete spinal cord injury in theater must be balanced with operational needs, experience, logistical support, and medevac capabilities. If spinal stabilization is performed in theater, an instrument system that is compatible with the systems or equipment available at higher echelons of care should be used, in case additional or revision surgery is required. Other patients with spine injuries, such as some non-coalition, third country and local nationals will need to be stabilized as best as possible using available methods at the Role 3.

Spinal instrumentation downrange is not without its challenges and is often performed with the understanding that additional procedures may need to be performed. A retrospective review of 50 consecutive surgical cases (30 treated at Role 3 and 20 treated at Role 4) between 2010-2011 demonstrated a doubling of perioperative complications and a 23% vs. 0% rate of additional spinal surgery for those treated in the Role 3 facility versus those delayed until Role 4. There was no significant difference in neurological recovery rate between these 2 cohorts. Emergent surgical decompression by thoracic or lumbar laminectomy for severe canal compromise in incomplete spinal cord injured patients, followed by staged surgical stabilization at Role 4 resulted in neurological improvement in 2 of 3 of these cases, suggesting that in the setting of severe stenosis with progressive neurological deficit, that staged laminectomy at the Role 3 facility, which is a faster, simpler procedure with less demand on the surgical and logistical support team in the deployed setting, followed by definitive stabilization at the fixed Role 4 facility, is another option in some cases.²¹

Neurological recovery is not the only purported benefit of early surgical intervention following SCI. Theoretical benefits of early operative stabilization of spinal injuries sustained in combat include earlier mobilization (diminishing DVT risk and improving pulmonary toilet), better analgesia during transport and protection of the neural elements. However, since over half of these patients have concomitant limb or pelvic injuries ("point of first contact fractures" in the combat burst injury) and/or significant hemodynamic distress, the advantages of early mobilization noted in the civilian setting do not translate to combat spine fractures that are managed across echelons of care.²²

PENETRATING SPINE INJURIES

SURGICAL INTERVENTION

The need for surgical intervention of penetrating spine injuries is sometimes unclear and staged debridement of the wound may be required given the cavitary injury to soft tissues. Indications for surgery may include progressive neurologic deficit, incomplete deficit (particularly if a missile or fragment is still within the canal) or the presence of a CSF leak. There is no new evidence from the current conflict to support that complete SCI from a penetrating mechanism has a significant change of clinical improvement. Surgery, if required, should be performed when the patient is in the most optimal state. The cavitation effect in addition to direct trauma from combat munitions and blast fragments produces severe anatomic injury that has proven irrecoverable, even in some case in which the fragment never penetrated the spinal canal. If surgery is undertaken, good dural closure is paramount. Anterior and oblique entry to the lumbar and lower thoracic spine are at increased risk of

infectious complications.²³ If instability is present, infectious risks and neurologic status are key factors to determining the need for and timing of surgical intervention.

TREATMENT

In 2010, Klimo et al produced a triservice, military consensus statement in regards to treatment recommendations for penetrating spinal injury. Based on the literature, they concluded that there is still ambiguity in regards to the role of decompression in an attempt to regain neurological function. For an incomplete injury with continued canal compromise, decompression, if attempted, should be done within 24-48 hours. If instability is present, stabilization should be considered at the time of surgery.²⁴ The consensus statement also empowered the deployed spine surgeon to make the final treatment decision based on their clinical judgment. Infectious risks and neurologic status are additional key factors to determining the need for and timing of surgical intervention.

Cefazolin 2 gm IV q 8 hrs for 24-72 hours is sufficient for penetrating spine injuries without evidence of contamination. Fragments passing through contaminated viscus structures (e.g., esophagus and colon) require extended spectrum anti-microbial coverage of enteric organisms for a longer period of time (e.g., 3rd generation cephalosporin for 7-10 days) for prophylaxis against osteomyelitis.²⁵ Broad spectrum coverage with good CSF penetration is also recommended for open wounds with a CSF leak.

PERFORMANCE IMPROVEMENT (PI) MONITORING

INTENT (EXPECTED OUTCOMES)

- A complete and thorough neurologic exam is performed on all patients with known or suspected spinal injuries and it is documented in the patient's medical record.
- There is no proven benefit to the use of steroids in penetrating or blunt spinal cord injury so steroids are not used in these patients.
- In patients with unstable TLS spine injuries, the vacuum spine board is used for transfer out of theater.
- For optimal care of these patients across the continuum, the JTTS C-spine Clearance Status sheet and Trauma Resuscitation Record (DD Form 3019) is utilized at the time of final disposition of the patient and documentation is complete.
- Obtunded US patients requiring C-spine clearance have a C-spine collar in place at the time of transfer to an Echelon IV facility.

PERFORMANCE/ADHERENCE MEASURES

- In patients with known or suspected spine injuries, the ASIA or Combat Neuro Exam worksheet was utilized to document adequately the patient's neurologic status and the documentation was placed in the patient's medical record.
- Steroids were not used in the management of patients with penetrating or blunt spinal cord injuries.
- In patients with known or suspected unstable spine fractures (3 column instability) being evacuated out of theater, the vacuum spine board was used for transport.
- The JTS C-spine Clearance Status sheet or Trauma Resuscitation Record (DD Form 3019) was utilized and documentation was complete at the time of final disposition of all patients requiring C-spine clearance at the local MTF.
- All obtunded patients (intubated; GCS \leq 8) requiring C-spine clearance had CT imaging at a Role 3 facility.

- All obtunded US patients, in addition to the above, had a C-spine collar in place at the time of transfer to an Echelon IV facility.
- All US patients with abnormal C-spine imaging had a C-spine collar in place at the time of transfer to an Echelon IV facility.

DATA SOURCE

- Patient Record and the ASIA or Combat Neuro Exam worksheet
- Department of Defense Trauma Registry (DoDTR)

SYSTEM REPORTING & FREQUENCY

The above constitutes the minimum criteria for PI monitoring of this CPG. System reporting will be performed annually; additional PI monitoring and system reporting may be performed as needed.

The system review and data analysis will be performed by the Joint Trauma System (JTS) Director and the Performance Improvement Branch.

RESPONSIBILITIES

It is the trauma team leader's responsibility to ensure familiarity, appropriate compliance and PI monitoring at the local level with this CPG.

REFERENCES

1. Blair JA, Patzkowski JC, Schoenfeld AJ, Cross Rivera JD, Grenier ES, Lehman RA, Hsu JR, Skeletal Trauma Research Consortium (STReC). Are spine injuries sustained in battle truly different? The Spine Journal. 2012; 12 (9):824-829.
2. Blair JA, Possley DR, Petfield JL, Schoenfeld AJ, Lehman RA, Hsu JR, MD, Skeletal Trauma Research Consortium (STReC). Military penetrating spine injuries compared with blunt. The Spine Journal. 2012; 12(9):762-76.
3. Tator CH, Duncan EG, Edmonds VE, et al. Comparison of surgical and conservative management in 208 patients with acute spinal cord injury. Can J Neurol Sci. 1987;14(1):60-69.
4. Krompinger WJ, Frederickson BE, Mino DE, et al. Conservative treatment of fracture of the thoracic and lumbar spine. Orthoped Clin North Am. 1986; 17(1):161-170.
5. Fehlings MG, Vaccaro A, Wilson JR, Singh A, et al. Early versus delayed decompression for traumatic cervical spinal cord injury: results of the surgical timing in acute spinal cord injury study (STASCIS). PLoS ONE. 2012; 7(2):e32037.
6. Walters BC, Hadley MN, Hurlbert RJ, Aarabi B, Dhall SS, Gelb DE, Harrigan MR, Rozelle CJ, Ryken TC, Theodore N; American Association of Neurological Surgeons; Congress of Neurological Surgeons. Guidelines for the management of acute cervical spine and spinal cord injuries: 2013 update. Neurosurgery. 2013; 60 Suppl 1:82-91.
7. Hoffman JR, Mower WR, Wolfson AB, et al. Validity of a set of clinical criteria to rule out injury to the cervical spine in patients with blunt trauma. New Engl J Med. 2000; 343:94-99.
8. Arishita GI, Vaver JS, Bellamy RF. Cervical spine immobilization of penetrating neck wounds in a hostile environment. J Trauma. 1989; 29:332-7.

9. Mahoney PF, Steinbruner D, Mazur R, et al. Cervical spine protection in a combat zone. *Injury*. 2007; 38:1222-20.
10. Patel MB¹, Humble SS, Cullinane DC, Day MA, Jawa RS, Devin CJ, Delozier MS, Smith LM, Smith MA, Capella JM, Long AM, Cheng JS, Leath TC, Falck-Ytter Y, Haut ER, Como JJ Cervical spine collar clearance in the obtunded adult blunt trauma patient: a systematic review and practice management guideline from the Eastern Association for the Surgery of Trauma. *J Trauma Acute Care Surg*. 2015; 78(2):430-41.
11. Como JJ, Leukhardt WH, Anderson JS, et al. Computed tomography alone may clear the cervical spine in obtunded blunt trauma patients: A prospective evaluation of a revised protocol. *J Trauma*. 2011; 70:345-51.
12. Anderson PA, Gugala Z, Lindsey RW, Schoenfeld AJ, Harris MB. Clearing the cervical spine in the blunt trauma patient. *J Am Acad Orthop Surg*. 2010; 18(3):149-59.
13. Schoenfeld AJ, Bono CM, McGuire KJ, Warholc N, Harris MB. Computed tomography alone versus computed tomography and magnetic resonance imaging in the identification of occult injuries to the cervical spine: a meta-analysis. *J Trauma*. 2010; 68(1):109-13
14. Simon JB, Schoenfeld AJ, Katz JN, Kamath AF, Wood K, Bono CM, Harris MB. Are "normal" multidetector computed tomographic scans sufficient to allow collar removal in the trauma patient? *J Trauma*. 2010; 68(1):103-8.
15. Mok JM, Jackson KL, Fang R, Freedman BA. Effect of vacuum spine board immobilization on incidence of pressure ulcers during evacuation of military casualties from theater. *Spine J*. 2013; 13(12):1801-8.
16. Yablon IG, Palumbo N, Spatz E, et al. Nerve root recovery in complete injuries of the cervical spine. *Spine*. 1991;16(10 Suppl):S518-521.
17. McQueen JD, Khan MI. Evaluation of patients with cervical spine lesions. In: *Cervical Spine Research Society, Editorial Subcommittee, editors. The cervical spine*. Philadelphia: JB Lippencott; 1983.
18. Dolan EJ, Tator CH, Endrenyi L. The value of decompression for acute experimental spinal cord compression injury. *J Neurosurg*. 1980; 53(6):749-755.
19. Rivlin AS, Tator CH. Effect of duration of acute spinal cord compression in a new acute cord injury model in a rat. *Surg Neurol*. 1978; 10(1):38-43.
20. Dvorak MF, Noonan VK, Fallah N, Fisher CG, Finkelstein J, Kwon BK, Rivers CS, Ahn H, Paquet J, Tsai EC, Townson A, Attabib N, Bailey CS, Christie SD, Drew B, Fourney DR, Fox R, Hurlbert RJ, Johnson MG, Linassi AG, Parent S, Fehlings MG; RHSCIR Network. The influence of time from injury to surgery on motor recovery and length of hospital stay in acute traumatic spinal cord injury: an observational Canadian cohort study. *J Neurotrauma*. 2015; 32(9):645-54.
21. Schoenfeld AJ, Mok JM, Cameron B, Jackson KL, Serrano JA, Freedman BA. Evaluation of immediate postoperative complications and outcomes among military personnel treated for spinal trauma in Afghanistan: a cohort-control study of 50 cases. *J Spinal Disord Tech*. 2014; 27(7):376-81.
22. Freedman BA, Serrano JA, Belmont PJ Jr, Jackson KL, Cameron B, Neal CJ, Wells R, Yeoman C, Schoenfeld AJ. The combat burst fracture study--results of a cohort analysis of the most prevalent combat specific mechanism of major thoracolumbar spinal injury. *Arch Orthop Trauma Surg*. 2014;134(10):1353-9.
23. Duz B, Cansever T, Secer HI, Kahraman S, Daneyemez MK, Gonul E: Evaluation of spinal missile injuries with respect to bullet trajectory, surgical indications and timing of surgical intervention: a new guideline. *Spine*. 2008; 33: E746-53.

24. Klimo P Jr, Ragel BT, Rosner M, Gluf W, McCafferty R. Can surgery improve neurological function in penetrating spine injury? A review of the military and civilian literature and treatment recommendations for military neurosurgeons. *Neurosurg Focus*. 2010; 28(5): E4.
25. Bono CM. Heary RF. Gunshot wounds to the spine. *Spine J*. 2004; 4(2):230-40.

APPENDIX A: AMERICAN SPINAL INJURY ASSOCIATION (ASIA) WORKSHEET

Use this worksheet to document neurological injury.

Page 1 of 2

INTERNATIONAL STANDARDS FOR NEUROLOGICAL CLASSIFICATION OF SPINAL CORD INJURY (ISNCSCI)		Patient Name _____ Date/Time of Exam _____ Examiner Name _____ Signature _____				
RIGHT	MOTOR KEY MUSCLES C5 Elbow flexors C6 Wrist extensors C7 Elbow extensors C8 Finger flexors T1 Finger abductors (little finger) L2 Hip flexors L3 Knee extensors L4 Ankle dorsiflexors L5 Long toe extensors S1 Ankle plantar flexors	SENSORY KEY SENSORY POINTS Light Touch (LTR) Pin Prick (PPR) C2 C3 C4 T2 T3 T4 T5 T6 T7 T8 T9 T10 T11 T12 L1 S2 S3 S4-5		SENSORY KEY SENSORY POINTS Light Touch (LTL) Pin Prick (PPL) C2 C3 C4 T2 T3 T4 T5 T6 T7 T8 T9 T10 T11 T12 L1 S2 S3 S4-5	MOTOR KEY MUSCLES C5 Elbow flexors C6 Wrist extensors C7 Elbow extensors C8 Finger flexors T1 Finger abductors (little finger) L2 Hip flexors L3 Knee extensors L4 Ankle dorsiflexors L5 Long toe extensors S1 Ankle plantar flexors	LEFT
UER (Upper Extremity Right) Comments (Non-key Muscle? Reason for NT? Pain?): <div style="border: 1px solid black; height: 100px; width: 100%;"></div>						UEL (Upper Extremity Left)
LER (Lower Extremity Right) (VAC) Voluntary Anal Contraction (Yes/No) <input type="checkbox"/>						LEL (Lower Extremity Left) (DAP) Deep Anal Pressure (Yes/No) <input type="checkbox"/>
RIGHT TOTALS (MAXIMUM) (50) (56) (56)				LEFT TOTALS (MAXIMUM) (50) (56) (56)		
MOTOR SUBSCORES UER <input type="text"/> + UEL <input type="text"/> = UEMS TOTAL <input type="text"/> (MAX (25) (25) (50)) LER <input type="text"/> + LEL <input type="text"/> = LEMS TOTAL <input type="text"/> (MAX (25) (25) (50))						
SENSORY SUBSCORES LTR <input type="text"/> + LTL <input type="text"/> = LT TOTAL <input type="text"/> (MAX (56) (56) (112)) PPR <input type="text"/> + PPL <input type="text"/> = PP TOTAL <input type="text"/> (MAX (56) (56) (112))						
NEUROLOGICAL LEVELS Steps 1-5 for classification as on reverse 1. SENSORY <input type="text"/> R <input type="text"/> L <input type="text"/> 2. MOTOR <input type="text"/> R <input type="text"/> L <input type="text"/> 3. NEUROLOGICAL LEVEL OF INJURY (NLI) <input type="text"/> 4. COMPLETE OR INCOMPLETE? <input type="text"/> Incomplete = Any sensory or motor function in S4-5 5. ASIA IMPAIRMENT SCALE (AIS) <input type="text"/> (In complete injuries only) ZONE OF PARTIAL PRESERVATION Most caudal level with any innervation SENSORY <input type="text"/> R <input type="text"/> L <input type="text"/> MOTOR <input type="text"/> R <input type="text"/> L <input type="text"/>						

This form may be copied freely but should not be altered without permission from the American Spinal Injury Association.

REV 11/15

Muscle Function Grading

- 0 = total paralysis
 1 = palpable or visible contraction
 2 = active movement, full range of motion (ROM) with gravity eliminated
 3 = active movement, full ROM against gravity
 4 = active movement, full ROM against gravity and moderate resistance in a muscle specific position
 5 = (normal) active movement, full ROM against gravity and full resistance in a functional muscle position expected from an otherwise unimpaired person
 5* = (normal) active movement, full ROM against gravity and sufficient resistance to be considered normal if identified inhibiting factors (i.e. pain, disuse) were not present
 NT = not testable (i.e. due to immobilization, severe pain such that the patient cannot be graded, amputation of limb, or contracture of > 50% of the normal ROM)

Sensory Grading

- 0 = Absent
 1 = Altered, either decreased/impaired sensation or hypersensitivity
 2 = Normal
 NT = Not testable

When to Test Non-Key Muscles:

In a patient with an apparent AIS B classification, non-key muscle functions more than 3 levels below the motor level on each side should be tested to most accurately classify the injury (differentiate between AIS B and C).

Movement	Root level
Shoulder: Flexion, extension, abduction, adduction, internal and external rotation	C5
Elbow: Supination	
Wrist: Flexion	C6
Finger: Flexion at proximal joint, extension.	C7
Thumb: Flexion, extension and abduction in plane of thumb	
Finger: Flexion at MCP joint	C8
Thumb: Opposition, adduction and abduction perpendicular to palm	
Finger: Abduction of the index finger	T1
Hip: Adduction	L2
Hip: External rotation	L3
Hip: Extension, abduction, internal rotation	L4
Knee: Flexion	
Ankle: Inversion and eversion	
Toe: MP and IP extension	
Hallux and Toe: DIP and PIP flexion and abduction	L5
Hallux: Adduction	S1

ASIA Impairment Scale (AIS)

A = Complete. No sensory or motor function is preserved in the sacral segments S4-5.

B = Sensory Incomplete. Sensory but not motor function is preserved below the neurological level and includes the sacral segments S4-5 (light touch or pin prick at S4-5 or deep anal pressure) AND no motor function is preserved more than three levels below the motor level on either side of the body.

C = Motor Incomplete. Motor function is preserved at the most caudal sacral segments for voluntary anal contraction (VAC) OR the patient meets the criteria for sensory incomplete status (sensory function preserved at the most caudal sacral segments (S4-S5) by LT, PP or DAP), and has some sparing of motor function more than three levels below the ipsilateral motor level on either side of the body.
 (This includes key or non-key muscle functions to determine motor incomplete status.) For AIS C – less than half of key muscle functions below the single NLI have a muscle grade \geq 3.

D = Motor Incomplete. Motor incomplete status as defined above, with at least half (half or more) of key muscle functions below the single NLI having a muscle grade \geq 3.

E = Normal. If sensation and motor function as tested with the ISNCSCI are graded as normal in all segments, and the patient had prior deficits, then the AIS grade is E. Someone without an initial SCI does not receive an AIS grade.

Using ND: To document the sensory, motor and NLI levels, the ASIA Impairment Scale grade, and/or the zone of partial preservation (ZPP) when they are unable to be determined based on the examination results.

**Steps in Classification**

The following order is recommended for determining the classification of individuals with SCI.

1. Determine sensory levels for right and left sides.

The sensory level is the most caudal, intact dermatome for both pin prick and light touch sensation.

2. Determine motor levels for right and left sides.

Defined by the lowest key muscle function that has a grade of at least 3 (on supine testing), providing the key muscle functions represented by segments above that level are judged to be intact (graded as a 5).

Note: in regions where there is no myotome to test, the motor level is presumed to be the same as the sensory level, if testable motor function above that level is also normal.

3. Determine the neurological level of injury (NLI)

This refers to the most caudal segment of the cord with intact sensation and antigravity (3 or more) muscle function strength, provided that there is normal (intact) sensory and motor function rostrally respectively.

The NLI is the most cephalad of the sensory and motor levels determined in steps 1 and 2.

4. Determine whether the injury is Complete or Incomplete.

(i.e. absence or presence of sacral sparing)

If voluntary anal contraction = **No** AND all S4-5 sensory scores = **0**

AND deep anal pressure = **No**, then injury is **Complete**.

Otherwise, injury is **Incomplete**.

5. Determine ASIA Impairment Scale (AIS) Grade:

Is injury Complete? If YES, AIS=A and can record ZPP (lowest dermatome or myotome on each side with some preservation)

NO ↓

Is injury Motor Complete? If YES, AIS=B

NO ↓

(No=voluntary anal contraction OR motor function more than three levels below the motor level on a given side, if the patient has sensory incomplete classification)

Are at least half (half or more) of the key muscles below the neurological level of injury graded 3 or better?

NO ↓

AIS=C

YES ↓

AIS=D

If sensation and motor function is normal in all segments, AIS=E

Note: AIS E is used in follow-up testing when an individual with a documented SCI has recovered normal function. If at initial testing no deficits are found, the individual is neurologically intact; the ASIA Impairment Scale does not apply.

APPENDIX B: COMBAT NEURO EXAM WORKSHEET

- ❖ Need Safety Pin or Needle
- ❖ Perform all elements for all patients with a fracture of the vertebral body (excludes stable isolated transverse or spinous process fractures) noted on CT scan.

DATE: _____ TIME: _____

Fractured Vertebrae: (circle all that apply)

C1 C2 C3 C4 C5 C6 C7

T1 T2 T3 T4 T5 T6 T7 T8 T9 T10 T11 T12

L1 L2 L3 L4 L5 Sacrum

MOI: [Vehicle vs. IED] [Dismounted IED] [Fall from Ht] [Aircraft Crash] [GSW] [OTHER]

Alertness at time of exam: [Intubated/Sedated] [Intubated/Alert/Compliant] [Extubated]

External Fixation: [RUE] [LUE] [RLE] [LLE] Splint: [RUE] [LUE] [RLE] [LLE]

Motor Strength:

Elbow Flexion (C5)

LEFT: [] No Motion [] Motion against gravity [] Normal [] [*] [] NT

RIGHT: [] No Motion [] Motion against gravity [] Normal [] [*] [] NT

Wrist Extension (C6)

LEFT: [] No Motion [] Motion against gravity [] Normal [] [*] [] NT

RIGHT: [] No Motion [] Motion against gravity [] Normal [] [*] [] NT

Elbow Extension (C7)

LEFT: [] No Motion [] Motion against gravity [] Normal [] [*] [] NT

RIGHT: [] No Motion [] Motion against gravity [] Normal [] [*] [] NT

MF DIP Flex (C8)

LEFT: [] No Motion [] Motion against gravity [] Normal [] [*] [] NT

RIGHT: [] No Motion [] Motion against gravity [] Normal [] [*] [] NT

SF Abduction (T1)

LEFT: [] No Motion [] Motion against gravity [] Normal [] [*] [] NT

RIGHT: [] No Motion [] Motion against gravity [] Normal [] [*] [] NT

Hip Flexion (L2)

LEFT: [] No Motion [] Motion against gravity [] Normal [] [*] [] NT

RIGHT: [] No Motion [] Motion against gravity [] Normal [] [*] [] NT

Knee Extension (L3)

LEFT: [] No Motion [] Motion against gravity [] Normal [] [*] [] NT

RIGHT: [] No Motion [] Motion against gravity [] Normal [] [*] [] NT

Ankle Dorsiflexion (L4)

LEFT: [] No Motion [] Motion against gravity [] Normal [] [*] [] NT

RIGHT: [] No Motion [] Motion against gravity [] Normal [] [*] [] NT

Great Toe Extension (L5)

LEFT: [] No Motion [] Motion against gravity [] Normal [] [*] [] NT

RIGHT: [] No Motion [] Motion against gravity [] Normal [] [*] [] NT

Ankle Plantarflexion (S1)

LEFT: [] No Motion [] Motion against gravity [] Normal [] [*] [] NT

RIGHT: [] No Motion [] Motion against gravity [] Normal [] [*] [] NT

Rectal Exam:

Voluntary Anal Contraction	<input type="checkbox"/> None	<input type="checkbox"/> Weak	<input type="checkbox"/> Normal
Tone	<input type="checkbox"/> None	<input type="checkbox"/> Weak	<input type="checkbox"/> Normal
<u>Pinprick</u> Anal Sensation (S4/5)	<input type="checkbox"/> Absent	<input type="checkbox"/> Impaired	<input type="checkbox"/> Normal
Anal Wink	<input type="checkbox"/> Absent	<input type="checkbox"/> Present	

Sensation:

Start at Clavicle and progress inferiorly until light touch sensation is abnormal. Then, test pin prick at this level and prick with sharp and then with dull surface at each dermatome. Check the LOWEST level where the patient had reliable detection of sharp and dull sensation. Indicate if levels are different on Left or Right side.

<input type="checkbox"/> Clavicle (C3/4)	<input type="checkbox"/> Umbilicus (T10)
<input type="checkbox"/> Lateral Elbow (C5)	<input type="checkbox"/> Mid-Inguinal Crease (T12)
<input type="checkbox"/> Dorsal Thumb (C6)	<input type="checkbox"/> Medial Thigh (Prox 1/3) (L1)
<input type="checkbox"/> Dorsal MF (C7)	<input type="checkbox"/> Medial Thigh (Mid Point) (L2)
<input type="checkbox"/> Dorsal SF (C8)	<input type="checkbox"/> Medial Knee (L3)
<input type="checkbox"/> Medial Elbow (T1)	<input type="checkbox"/> Medial Ankle (L4)
<input type="checkbox"/> Nipple Level (T4)	<input type="checkbox"/> Dorsum Middle Toe (L5)
<input type="checkbox"/> Xiphoid Level (T6)	

Reflexes:

Bulbocavernosus	<input type="checkbox"/> Absent	<input type="checkbox"/> Present	<input type="checkbox"/> Indeterminate	<input type="checkbox"/> NT
Patella	LEFT: <input type="checkbox"/> Absent	<input type="checkbox"/> Present	RIGHT: <input type="checkbox"/> Absent	<input type="checkbox"/> Present
Clonus	LEFT: <input type="checkbox"/> Absent	<input type="checkbox"/> Present	RIGHT: <input type="checkbox"/> Absent	<input type="checkbox"/> Present
Foley:	<input type="checkbox"/> Present	<input type="checkbox"/> Voiding spontaneously without catheter		

ASIA Score: (circle score)

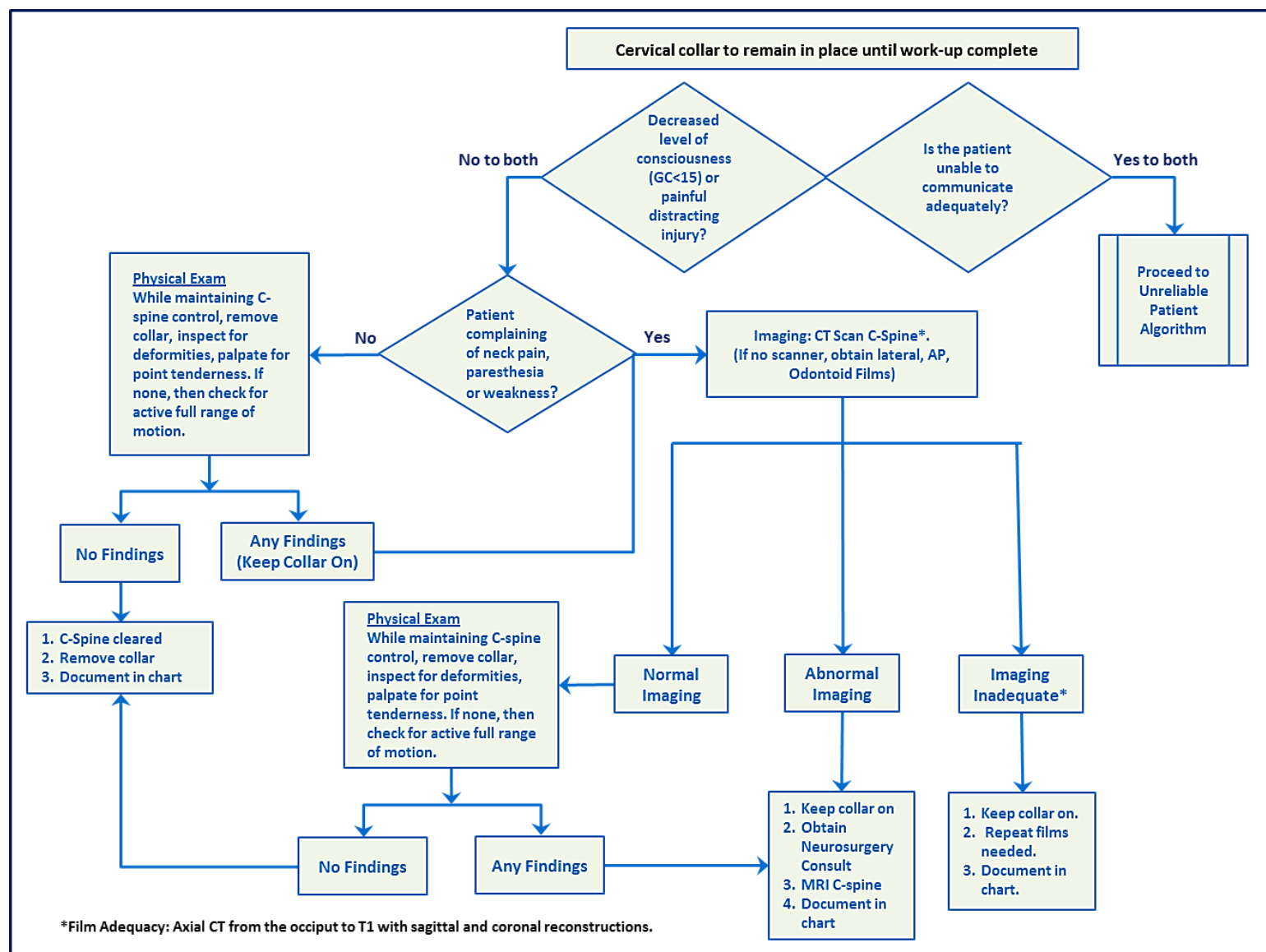
- [A] COMPLETE (no motor/sensory function below level of injury)
- [B] Pinprick sensation PRESENT at anus (S4/5) – NO Motor
- [C] <½ the muscles below level of injury have motion against gravity
- [D] >½ the muscles below level of injury have motion against gravity
- [E] Normal

NEURO LEVEL: _____ (Lowest level with normal sense and at least antigravity strength)

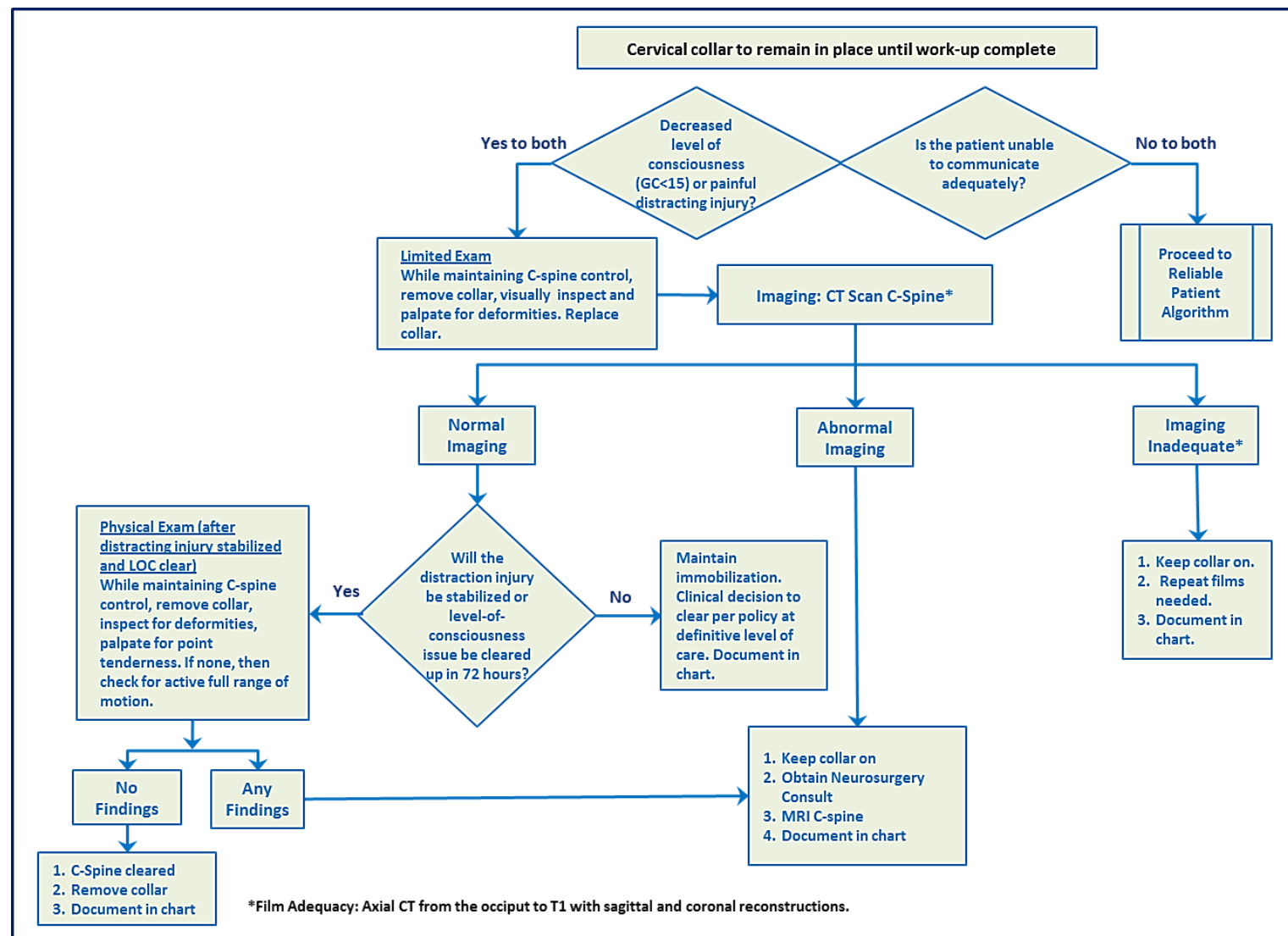
Incomplete Syndrome: (SCI – Occ-T11 Fx) (Conus – T12-L2 Fx) (CES – L3-Sacrum)

MF = middle finger; SF = small finger; * Suspect NORMAL strength, but limited due to pain; NT = Not Tested


APPENDIX C: CERVICAL SPINE CLEARANCE ALGORITHM RELIABLE PATIENT WITH NO NEUROLOGIC DEFICIT



APPENDIX D: CERVICAL SPINE CLEARANCE ALGORITHM UNRELIABLE PATIENT



APPENDIX E: CERVICAL SPINE CLEARANCE STATUS

 Cervical Spine Clearance Status Notes Joint Trauma System	
Mechanism: <input type="checkbox"/> Explosive <input type="checkbox"/> M/C <input type="checkbox"/> Fall <input type="checkbox"/> Other	
Notes: <input style="width: 100%;" type="text"/>	
Collar placed: <input type="checkbox"/> Prehospital <input type="checkbox"/> Hospital <input type="checkbox"/> No collar	
Patient reliable? <input type="checkbox"/> Yes <input type="checkbox"/> No Reason unreliable? <input type="checkbox"/> Altered Mental Status (GCS<15) <input type="checkbox"/> Significant Distracting Injury	
Notes: <input style="width: 100%;" type="text"/>	
Patient complaints <input type="checkbox"/> None <input type="checkbox"/> Neck pain (specify location:) <input style="width: 150px;" type="text"/> <input type="checkbox"/> Paresthesia	
Notes: <input style="width: 100%;" type="text"/>	
Physical Findings	
Inspection: <input type="checkbox"/> Normal <input type="checkbox"/> Abnormal specify: <input style="width: 150px;" type="text"/>	
Palpation: <input type="checkbox"/> Normal <input type="checkbox"/> Point tenderness <input type="checkbox"/> Deformity	
Notes: <input style="width: 100%;" type="text"/>	
Active range of motion: <input type="checkbox"/> Full <input type="checkbox"/> Limited specify: <input style="width: 150px;" type="text"/>	
Notes: <input style="width: 100%;" type="text"/>	
Imaging Studies (CT is standard. Films acceptable only when CT is unavailable.)	
CT scan: <input type="checkbox"/> Normal <input type="checkbox"/> Abnormal specify: <input style="width: 150px;" type="text"/>	
Notes: <input style="width: 100%;" type="text"/>	
Lateral: <input type="checkbox"/> Normal <input type="checkbox"/> Abnormal specify: <input style="width: 150px;" type="text"/>	
AP: <input type="checkbox"/> Normal <input type="checkbox"/> Abnormal specify: <input style="width: 150px;" type="text"/>	
Odontoid: <input type="checkbox"/> Normal <input type="checkbox"/> Abnormal specify: <input style="width: 150px;" type="text"/>	
C L E A R A N C E	
Cervical spine is:	
<input type="checkbox"/> CLEAR of significant injury and instability on the basis of the following:	
<input type="checkbox"/> Normal exam in completely reliable patient with no need for imaging	
<input type="checkbox"/> Normal imaging of full C-Spine and normal exam.	
<input type="checkbox"/> NOT CLEAR on the basis of the following:	
<input type="checkbox"/> Neurological complaint or abnormal physical exam finding	
<input type="checkbox"/> Abnormal imaging	
<input type="checkbox"/> Unreliable patient at time of evacuation/final disposition	
Physician name <input style="width: 150px;" type="text"/>	Physician signature <input style="width: 150px;" type="text"/>
MTF <input style="width: 150px;" type="text"/>	Date <input style="width: 50px;" type="text"/>
Medical Record (Rev. May 2018)	

APPENDIX F: ADDITIONAL INFORMATION REGARDING OFF-LABEL USES IN CPGS

PURPOSE

The purpose of this Appendix is to ensure an understanding of DoD policy and practice regarding inclusion in CPGs of “off-label” uses of U.S. Food and Drug Administration (FDA)–approved products. This applies to off-label uses with patients who are armed forces members.

BACKGROUND

Unapproved (i.e., “off-label”) uses of FDA-approved products are extremely common in American medicine and are usually not subject to any special regulations. However, under Federal law, in some circumstances, unapproved uses of approved drugs are subject to FDA regulations governing “investigational new drugs.” These circumstances include such uses as part of clinical trials, and in the military context, command required, unapproved uses. Some command requested unapproved uses may also be subject to special regulations.

ADDITIONAL INFORMATION REGARDING OFF-LABEL USES IN CPGS

The inclusion in CPGs of off-label uses is not a clinical trial, nor is it a command request or requirement. Further, it does not imply that the Military Health System requires that use by DoD health care practitioners or considers it to be the “standard of care.” Rather, the inclusion in CPGs of off-label uses is to inform the clinical judgment of the responsible health care practitioner by providing information regarding potential risks and benefits of treatment alternatives. The decision is for the clinical judgment of the responsible health care practitioner within the practitioner-patient relationship.

ADDITIONAL PROCEDURES**Balanced Discussion**

Consistent with this purpose, CPG discussions of off-label uses specifically state that they are uses not approved by the FDA. Further, such discussions are balanced in the presentation of appropriate clinical study data, including any such data that suggest caution in the use of the product and specifically including any FDA-issued warnings.

Quality Assurance Monitoring

With respect to such off-label uses, DoD procedure is to maintain a regular system of quality assurance monitoring of outcomes and known potential adverse events. For this reason, the importance of accurate clinical records is underscored.

Information to Patients

Good clinical practice includes the provision of appropriate information to patients. Each CPG discussing an unusual off-label use will address the issue of information to patients. When practicable, consideration will be given to including in an appendix an appropriate information sheet for distribution to patients, whether before or after use of the product. Information to patients should address in plain language: a) that the use is not approved by the FDA; b) the reasons why a DoD health care practitioner would decide to use the product for this purpose; and c) the potential risks associated with such use.