

JOINT TRAUMA SYSTEM K9 CLINICAL PRACTICE GUIDELINE



Normal Clinical Parameters for MWDs (K9 CPG: 02)

This Clinical Practice Guideline (CPG) outlines normal clinical parameters in Military Working Dogs (MWDs). It addresses unique canine anatomy for venous access and reviews routine cardiovascular monitoring.

CONTRIBUTORS

LTC Rebecca Baxter, VC, USA
LTC Rachel Acciacca, VC, USA

LTC Erin Long Mays, VC, USAR

Previous contributors: LTC (Ret) Michael Lagutchik, VC, USA; LTC Janice Baker, VC, USAR; MAJ Jamie Brown, VC, USA; COL (Ret) Walter Burghardt, BSC, USAF; LTC(P) Matthew Enroth, VC, USA; LTC Shannon Flournoy, VC, USA; LTC (Ret) James Giles, III, VC, USA; MAJ Patrick Grimm, VC, USA; LTC Jennifer Hiniker, VC, USA; COL Jacob Johnson, VC, USAR; COL (Ret) Kelly Mann, VC, USA; MAJ (Ret) Eric Storey, VC, USAR; LTC Matt Takara, VC, USA; MAJ (Ret) Todd Thomas, VC, USA; LT Cory Frappier, MC, USN

Original publication date: 19 Nov 2018

Publication Date: 05 May 2025

Supersedes: 19 Nov 2018

TABLE OF CONTENTS

BACKGROUND.....	2
NORMAL CLINICAL PARAMETERS.....	2
UNIQUE CLINICAL ANATOMY & VENOUS ACCESS.....	3
VENOUS BLOOD SAMPLING & IV CATHETERIZATION SITES	3
Cephalic Vein.....	3
Lateral Saphenous Vein.....	4
External Jugular Vein.....	5
ROUTINE CARDIOVASCULAR MONITORING.....	8
ELECTROCARDIOGRAMS	8
PULSE OXIMETRY	9
NON-INVASIVE BLOOD PRESSURE MONITORING	9
PREVENTION OF SELF-TRAUMA & REMOVAL OF DEVICES.....	10
REFERENCES.....	11
APPENDIX A: CLASS VIII MEDICAL MATERIEL	12

SUMMARY OF CHANGES

1. Added background information.
2. Updated bloodwork reference interval examples.
3. Annotated separate venous and arterial reference interval examples for blood gas.
4. Updated Appendix A.

BACKGROUND

Care provided to Military Working Dogs (MWDs) in an operational environment may be provided by veterinary and human healthcare providers. Understanding normal physiological parameters is essential for identifying abnormal clinical status in an MWD and assessing response to treatment.

Unique clinical anatomy of MWDs must also be understood to perform medical interventions and to monitor changes in physiologic status. MWDs will also traumatize medical devices and require additional interventions to maintain MWD safety.

NORMAL CLINICAL PARAMETERS

Table 1. Ranges for normal vital parameters in MWDs at rest.

NORMAL VITALS AT REST	
Temperature (rectal)	101.0° - 103.0° F
Heart rate	60 – 80 beats per minute
Respiratory rate	16 – 30 breaths per minute - Controlled panting is common in MWDs.
Blood pressure ¹	Systolic: 90 – 140 mmHg Diastolic: 50 – 80 mmHg Mean: 60 – 100 mmHg

Table 2 and Table 3 include normal bloodwork reference interval examples for MWDs.² Table 4 includes normal reference interval examples for blood gas.³ Each machine will have unique established reference intervals based on calibration for the sample type.

Table 2. Complete blood cell count parameters in canines.

BLOOD CELL COUNT PARAMETERS	
WBC (White Blood Cell)	$5.7 - 14.2 \times 10^3 / \mu\text{L}$
RBC (Red Blood Cell)	$5.7 - 8.5 \times 10^6 / \mu\text{L}$
Hgb (Hemoglobin)	14.1 – 20.1 g/dL
Hct (Hematocrit)	41 – 58 %
MCV (Mean Cell Volume)	64 – 76 fL
MCH (Mean Cell Hemoglobin)	21 – 26 pg
MCHC (Mean Cell Hemoglobin Concentration)	33 – 36 g/dL
Platelet Count	$186 - 545 \times 10^3 / \mu\text{L}$

Results from serum chemistry analyzers calibrated for human serum may be unreliable or misleading based on methodology for albumin and total calcium concentrations.

Table 3. Blood chemistry parameters in canines.

BLOOD CHEMISTRY PARAMETERS	
Albumin	3.2 – 4.1 g/dL
ALP (alkaline phosphatase)	7 – 115 U/L
ALT (alanine aminotransferase)	17 – 95 U/L
Amylase	322 – 1310 U/L
AST (aspartate aminotransferase)	18 – 56 U/L
Bicarbonate	14 – 24 mEq/L
BUN (blood urea nitrogen)	9 – 26 mg/dL
Calcium (total)	9.4 – 11.1 mg/dL
Chloride	106 – 114 mEq/L
CK (creatinine kinase)	64 – 314 U/L
Creatinine	0.6 – 1.4 mg/dL
GGT (gamma-glutamyl transferase)	0 – 8 U/L
Glucose	68 – 104 mg/dL
Potassium	4.1 – 5.4 mEq/L
Sodium	143 – 150 mEq/L
Total bilirubin	0 – 0.2 mg/dL
Total protein	5.5 – 7.2 g/dL
Lactate	< 2.5 mmol/L

Table 4. Blood gas parameters in canines.

BLOOD GAS PARAMETERS		
Value	Venous blood	Arterial blood
HCO ₃ ⁻	22.1 ± 2 mmol/L	21.4 ± 1.6 mmol/L
pCO ₂	42.1 ± 4.4 mmHg	36.8 ± 2.7 mmHg
pH	7.352 ± 0.02	7.395 ± 0.03
pO ₂	55 ± 9.6 mmHg	102.1 ± 6.8 mmHg

UNIQUE CLINICAL ANATOMY & VENOUS ACCESS

Dogs differ anatomically and physiologically in several key areas compared to humans. Knowledge of these differences will assist providers when managing MWDs.

Most MWDs are German Shepherd Dogs, Belgian Malinois and Labrador Retrievers, with a weight of 50 to 80 pounds (23 – 36 kilograms). Dose drugs based on actual body weight whenever possible.

VENOUS BLOOD SAMPLING & IV CATHETERIZATION SITES

Use the cephalic or lateral saphenous vein for routine blood sampling, drug administration, and routine intravenous (IV) fluid therapy. Use the external jugular vein for long-term IV fluid therapy, large volume fluid delivery, and repeated blood sampling.

Cephalic Vein

Figure 1 shows the location of the cephalic vein on the cranial (anterior) forearm. The accessory cephalic vein and cephalic vein join in a Y-shaped configuration distal (toward the carpus or wrist). Figure 2 shows proper technique for occlusion of the cephalic vein. An assistant will occlude the vein by extending the elbow joint and occluding the vein while rolling the vein outward at the elbow. Figure 3 shows proper location of an IV catheter in the cephalic vein.

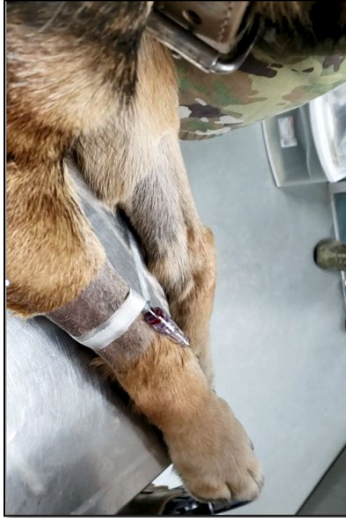
Figure 1. Cephalic vein location

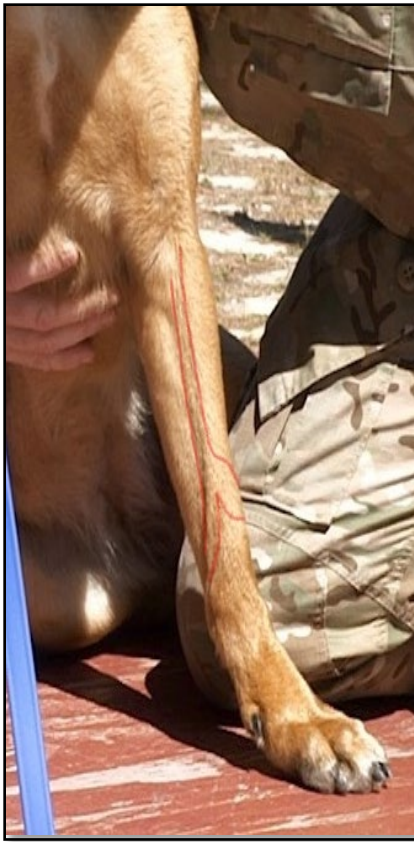

Figure 2. Occlusion of cephalic vein



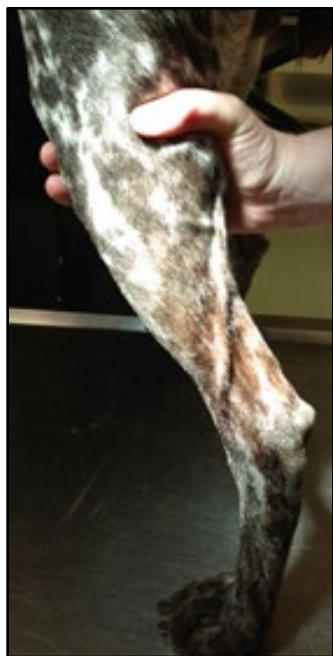Figure 3. Cephalic IV catheter placement



Lateral Saphenous Vein

Figure 4 shows the location of the lateral saphenous vein on the lateral aspect of the hind limb at the distal tibial area, coursing caudally and proximally from the hock (ankle) and over the gastrocnemius tendon.

Figure 4. Lateral saphenous vein location



External Jugular Vein

To access the external jugular vein, standard human central venous catheter kits can be used; the Seldinger technique is most reliable.

The external jugular vein is in the jugular furrow (Figure 5) and is punctured distal to the junction of the proximal tributaries. Clip the hair and perform a sterile preparation (including draping). Create a small skin nick using a #11 scalpel blade or an 18-gauge needle over the intended catheter insertion site to facilitate skin penetration (Figure 6).

A large bore over-the-needle catheter is inserted through the skin and directed caudally into the external jugular vein (Figure 7). The opposite hand can be used to occlude the vein. Following full insertion of the over-the-needle catheter (Figure 8), a Seldinger guide wire is inserted into the hub of the catheter (Figure 9).

The guide wire is advanced about two-thirds of the way, and then the catheter is removed, leaving the guidewire in place (Figure 10). It is essential to maintain control of the guidewire. A single or multi-lumen central venous catheter is advanced over the guidewire (Figure 11). Use of a dilator is often necessary before this step to enlarge the puncture in the skin and vessel to accommodate the catheter diameter.

The catheter is advanced into the external jugular vein (Figure 12). The guidewire should extend from the proximal end of the catheter. Remember to always maintain control of the guidewire. Once the catheter is fully inserted, the guidewire is removed, and an injection port is attached to the catheter hub (Figure 13).

Secure the catheter to the MWD's skin with suture through the wings of the catheter hub, and circumferentially around the catheter base (Figure 14). The central venous catheter should then be secured on the MWD's neck with roll gauze or cast padding (Figure 15) followed by non-adherent bandage material (Figure 16). At least two fingers should be able to be placed under the bandage to ensure it is not too tight. Always monitor the MWD for any signs of facial swelling or respiratory distress caused by the bandage being too tight.

Figure 5. Location of external jugular vein with optimal catheter insertion site.

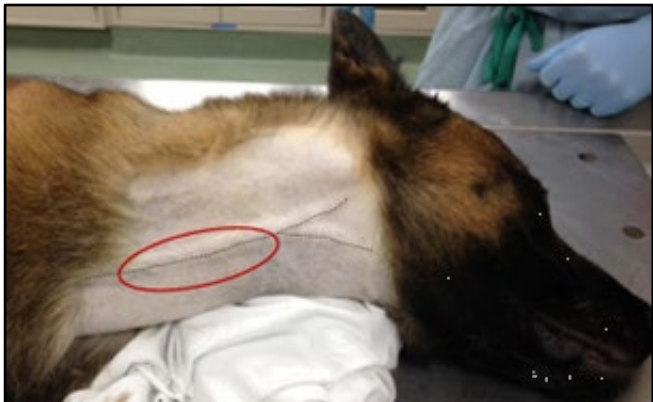

Figure 6. Skin nick to facilitate external jugular vein catheter placement.

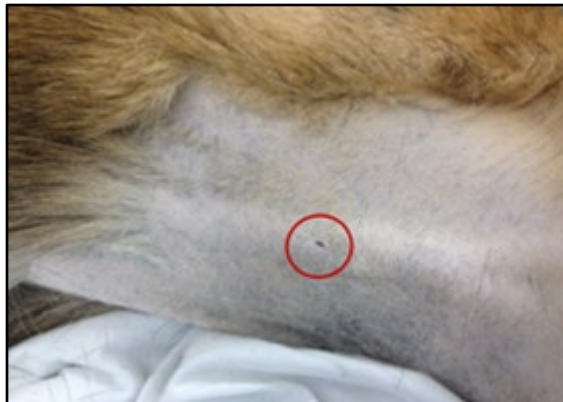

Figure 7. Insertion of over-the-needle catheter into the external jugular vein.

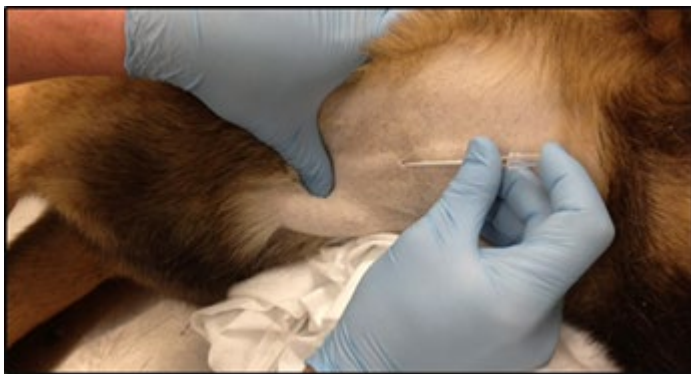

Figure 8. Full insertion of over-the-needle catheter into the external jugular vein.

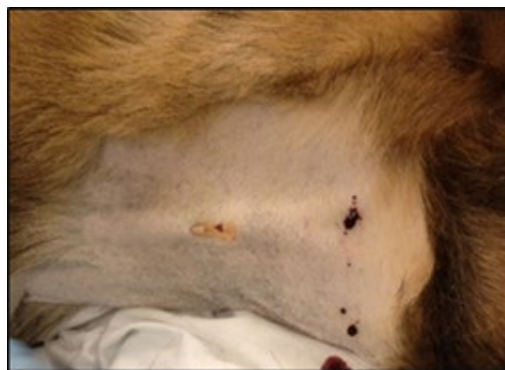

Figure 9. Insertion of Seldinger guide wire into the external jugular vein.

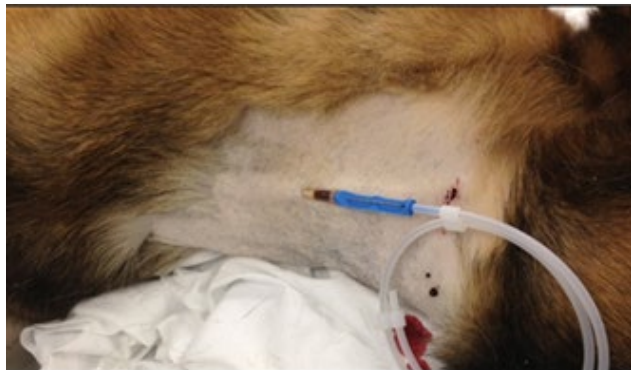

Figure 10. Advanced Seldinger guide wire caudally into the external jugular vein.

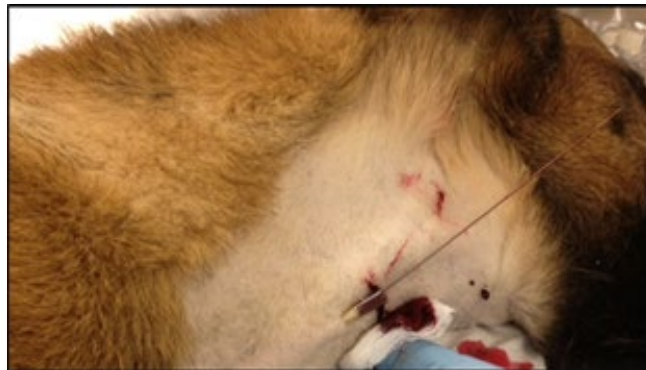

Figure 11. Advancement of central venous catheter over the Seldinger guide wire.

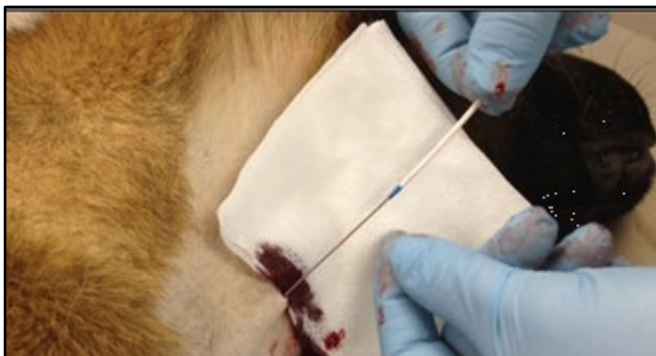


Figure 12. Advancement of central venous catheter into external jugular vein.

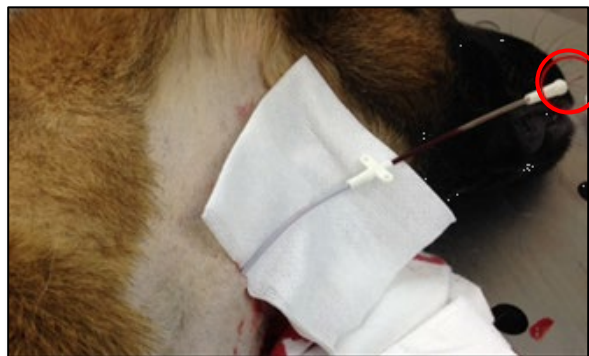

Figure 13. Full insertion of central venous catheter into external jugular vein.

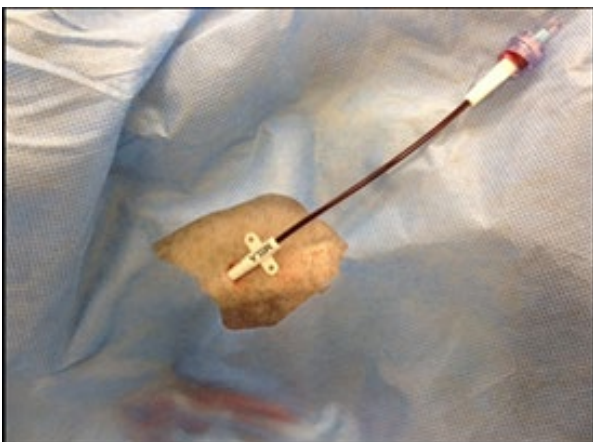

Figure 14. Secured central venous catheter to MWD skin.

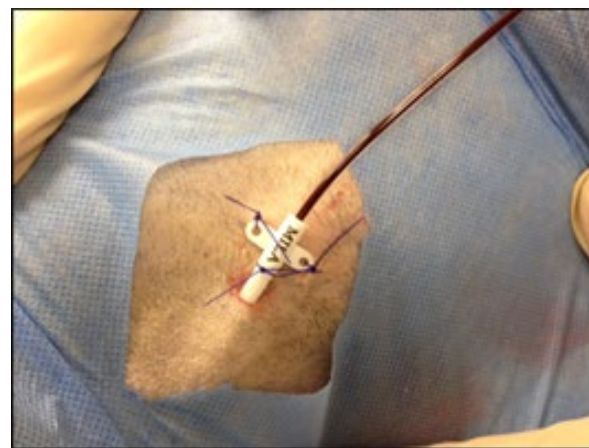


Figure 15. *Securing central venous catheter with roll gauze or cast padding.*

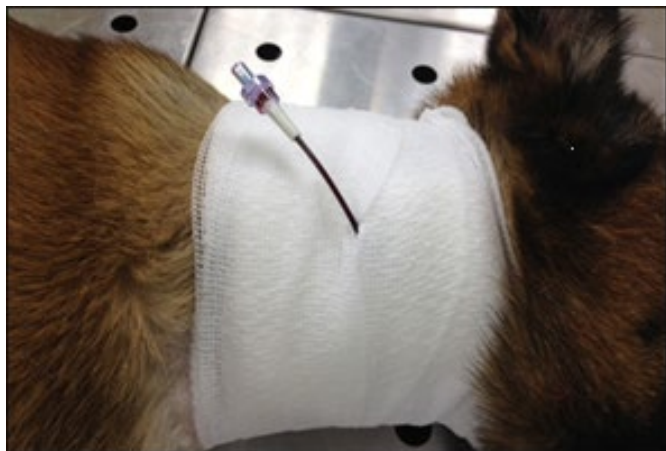
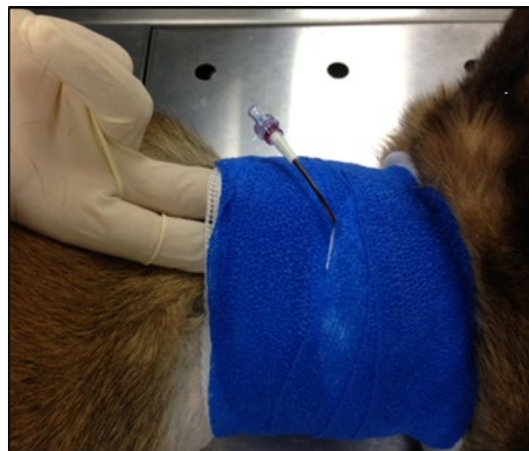
Figure 16. *Complete securement of central venous catheter with bandage material.*



ROUTINE CARDIOVASCULAR MONITORING

Heart sounds are best auscultated over the left lower lateral thoracic wall between the 4th and 5th intercostal spaces, typically where the elbow crosses the chest wall when the forelimb is pulled caudally.

The arterial pulse is best palpated at the femoral artery on the medial aspect of the proximal thigh in the inguinal area (Figure 17 and 18). The arterial pulse can also be palpated at the dorsal metatarsal artery on the dorso-medial aspect of the proximal hind paw, distal to the hock (ankle).

Figure 17. *Location for palpation of the femoral arterial pulse while dog is standing.*

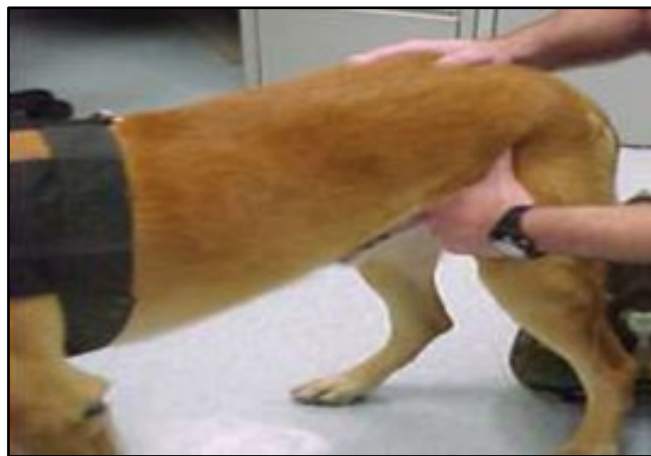
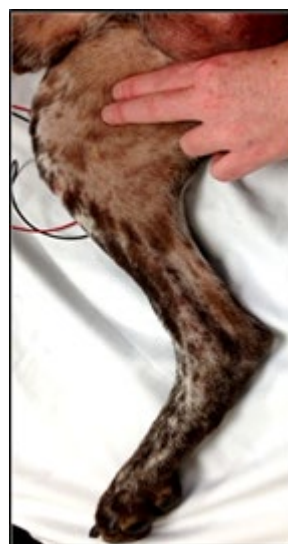
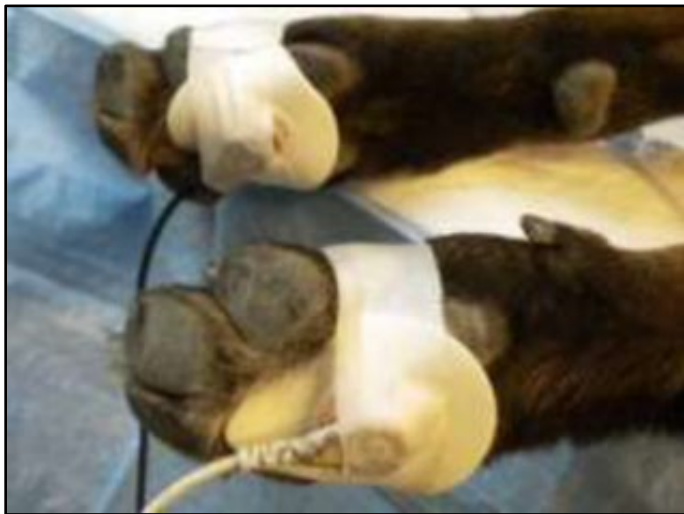Figure 18. *Location for palpation of the femoral arterial pulse from medial view of the hind limb.*



ELECTROCARDIOGRAMS

Electrocardiogram (ECG) electrodes should be taped to the pads of the paws (Figure 19 below) on the left forelimb (black lead), right forelimb (white lead), and left hind limb (red lead). Three-lead ECGs are sufficient. Canine ECG complexes resemble human complexes, with minor variations in key ECG intervals and possible inverted T-waves. Electrode or ultrasound gel may be required between the electrode and footpads to improve contact.

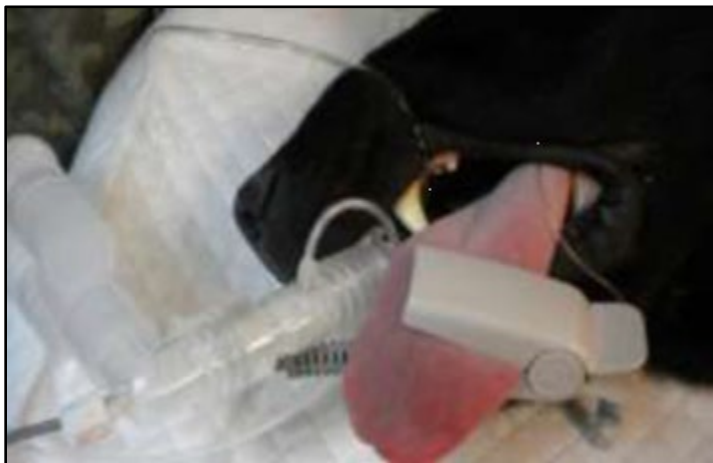Figure 19. Placement of ECG electrode pads.



PULSE OXIMETRY

Human pulse oximetry probes (typically finger probes) are best placed on the tongue for optimal reliability in unconscious, sedated or anesthetized MWDs (Figure 20) but can also be placed on the prepuce or vulva. In conscious dogs, use the ear pinna, lip fold, or flank skin fold. Although these are not optimal for pulse oximetry, these alternate sites generally yield reliable results. Normal pulse oximetry for an MWD is greater than 95%.

Figure 20. Placement of human pulse oximeter finger probe on tongue.



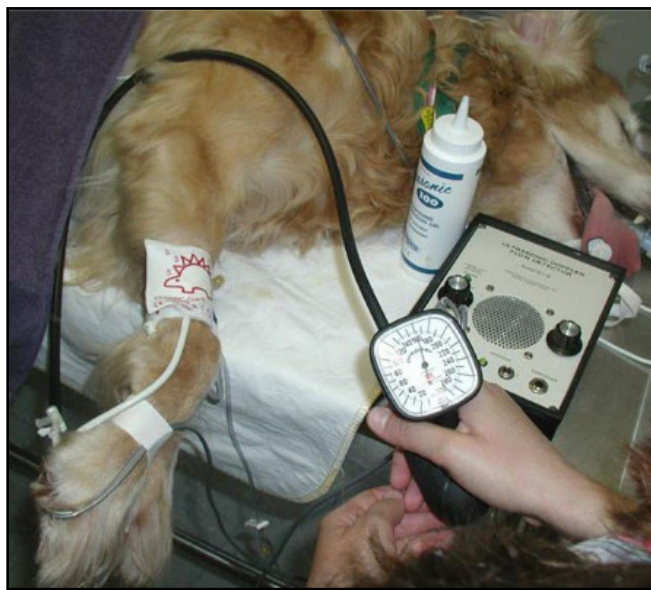NON-INVASIVE BLOOD PRESSURE MONITORING

Non-invasive blood pressure (NIBP) monitoring is accomplished with doppler or oscillometric techniques. Cuff size and patient positioning are critical to obtain accurate readings. The width of the cuff should be 30 - 40% of the limb circumference at the site of cuff placement.⁴ Human pediatric cuffs (size 6 to 8) fit most MWDs.

Common locations for doppler probe placement include the dorsal pedal artery, digital artery, and coccygeal artery (Figure 21 below). Patients should lie in lateral recumbency with the cuff positioned on the limb at the level of the right atrium.

Common locations for cuff placement for oscillometric measurements are over the dorsal metatarsal artery, lower forearm, and tail base.

Figure 21. Placement of doppler probe on digital artery with accompanying cuff placement.



PREVENTION OF SELF-TRAUMA & REMOVAL OF DEVICES

MWDs will chew at catheters, bandages and monitoring devices. They will lick and chew at wounds to the point of causing foreign body ingestion and self-trauma. Use basket muzzles in the immediate period of initial monitoring and care to prevent these unwanted behaviors.

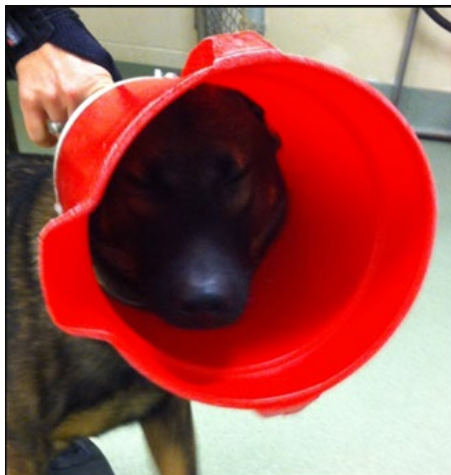Tape IV catheters around the entire circumference of the limb, including the hub and catheter adapter port to adequately secure the catheter. The tape should be snug but use caution to prevent excessive tightness that will result in distal limb edema. Monitor the MWD regularly and loosen the catheter tape if swelling or edema is noted.

For long-term management, an Elizabethan collar (e-collar) should be used. If the MWD quickly damages a standard e-collar, another simple option is to make a preventive device. The bottom of a standard bucket is removed, 4 to 5 holes are drilled in the base of the bucket, and cable ties are used through the holes to secure the bucket to the dog's collar. The bucket-collar combination is then applied. Figures 22 and 23 show the bucket technique and the appearance after application to the MWD.

Figure 22. Technique to make a bucket to prevent self-trauma by MWDs.



Figure 23. Bucket-collar device applied to an MWD



REFERENCES

- 1 Sierra LK and Savino E. Blood pressure monitoring from a veterinary nursing perspective, Part 1: Overview. Today's veterinary practice, Dec 19, 2014. <https://todaysveterinarypractice.com/cardiology/todays-technician-blood-pressure-monitoring-from-a-nursing-perspective-part-1-overview-of-blood-pressure-monitoring/>
- 2 Cornell University College of Veterinary Medicine. Animal Health Diagnostic Center. Laboratories. Clinical Pathology. Reference Intervals, 2025. <https://www.vet.cornell.edu/animal-health-diagnostic-center/laboratories/clinical-pathology/reference-intervals> .
- 3 Waddell, LS. The practitioner's acid-base primer: obtaining & interpreting blood gases. Today's Veterinary Practice, May/June 2023. <https://todaysveterinarypractice.com/clinical-pathology/the-practitioners-acid-base-primer-obtaining-interpreting-blood-gases> .
- 4 Acierno MJ, Brown S, Coleman AE, et al. ACVIM consensus statement: Guidelines for the identification, evaluation, and management of systemic hypertension in dogs and cats. J Vet Intern Med. 2018;32:1803-1822. <https://doi.org/10.1111/jvim.15331>

APPENDIX A: CLASS VIII MEDICAL MATERIEL

Based on the Normal Clinical Parameters for MWDs K9 CPG, for best practices for MWD care, the following medical materials are recommended:

Basic Monitoring Equipment

- Stethoscope
- Thermometer
- Non-invasive Blood Pressure (NIBP) monitoring device such as:
 - Sphygmomanometer
 - Oscillometric blood pressure monitor
 - Doppler ultrasound probe with blood pressure cuff
- Pulse oximeter
- ECG monitor

Diagnostic and Laboratory Tools

- Hematology analyzer
- Chemistry analyzer
- Portable chemistry analyzer (e.g., i-STAT)

Intravenous (IV) Catheter Placement Equipment and Supplies

- Peripheral IV catheters (various sizes, 18–22 gauge)
- IV extension sets and t-ports
- Central venous catheters (single – 14-16 gauge or multi-lumen – 7 French)
- Clippers
- Scrub (chlorhexidine or iodine based)
- Surgical drapes and sterile gloves

Sedation Supplies (as needed for IV catheter placement)

- Injectable sedatives (e.g., Dexmedetomidine)
- **NOTE:** *Some patients may require general anesthesia for central venous catheter placement. In these instances, refer to the Anesthesia and Analgesia K9 CPG.*

Additional Supplies

- Elastic bandages (e.g., VetWrap)
- Rolled gauze
- Sterile gauze pads and non-adherent dressings
- Medical tape
- Surgical instruments (scalpel handles, blades, scissors, forceps, needle drivers)
- Suture (non-absorbable)
- E-collars (Elizabethan collars) or buckets
- Muzzles (basket or soft, for safety during procedures)

For additional information including National Stock Number (NSN), please contact dha.ncr.med-log.list.lpr-cps@health.mil

DISCLAIMER: *This is not an exhaustive list. These are items identified to be important for the care of combat casualties.*